

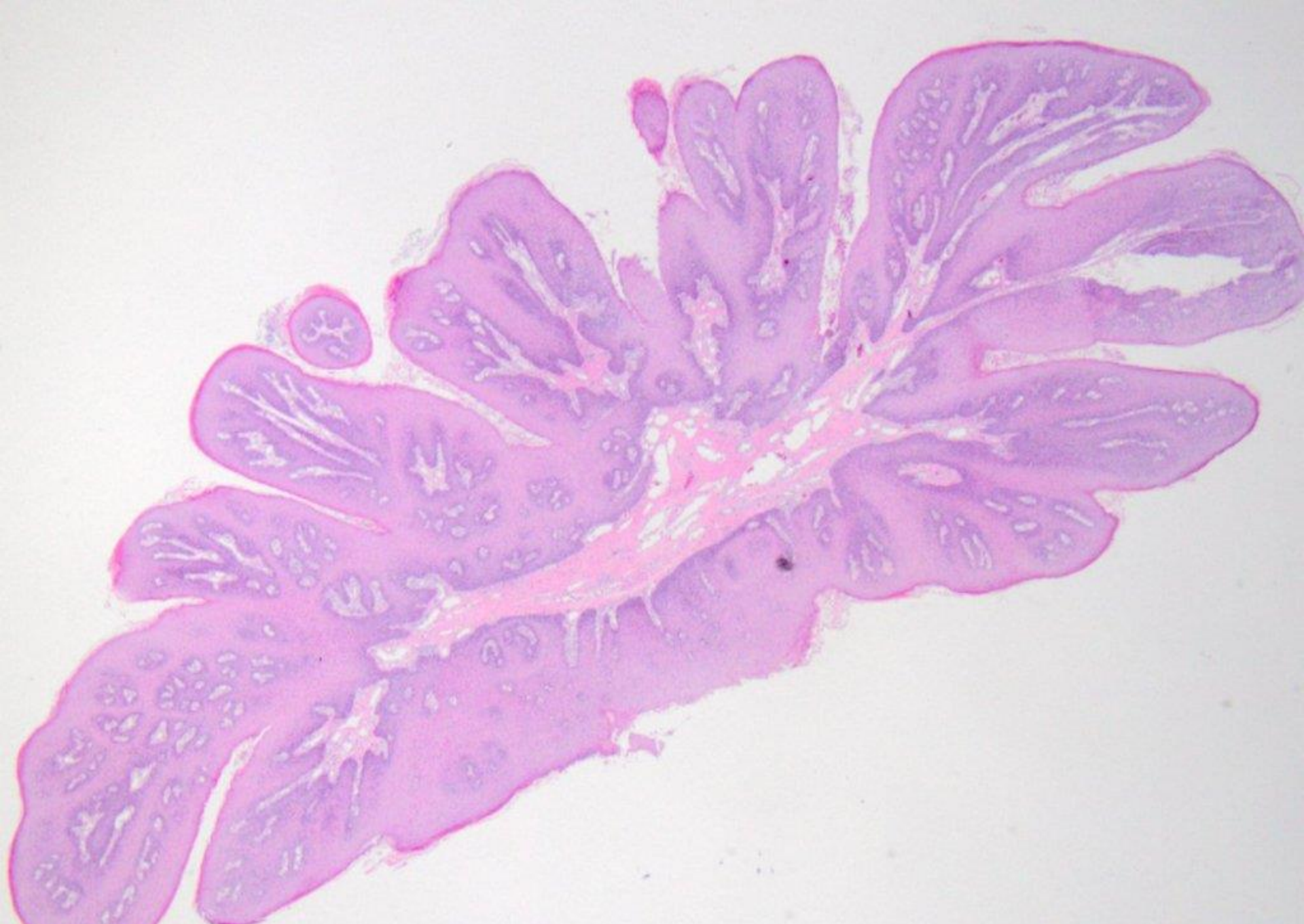
Oral Histopathology

Series 30

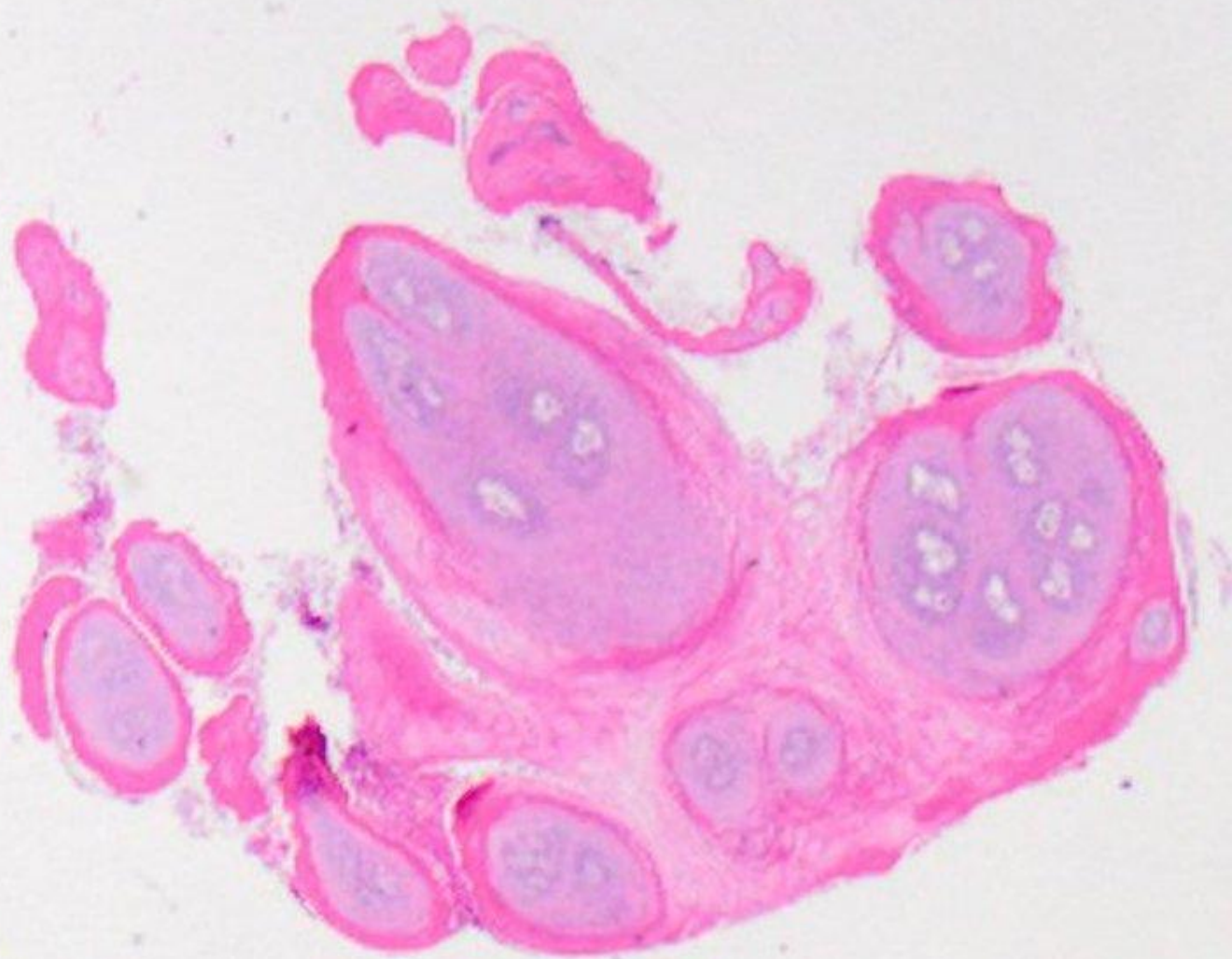
DAVID E. KLINGMAN, DMD

Diplomate, American Board of Oral and Maxillofacial Pathology

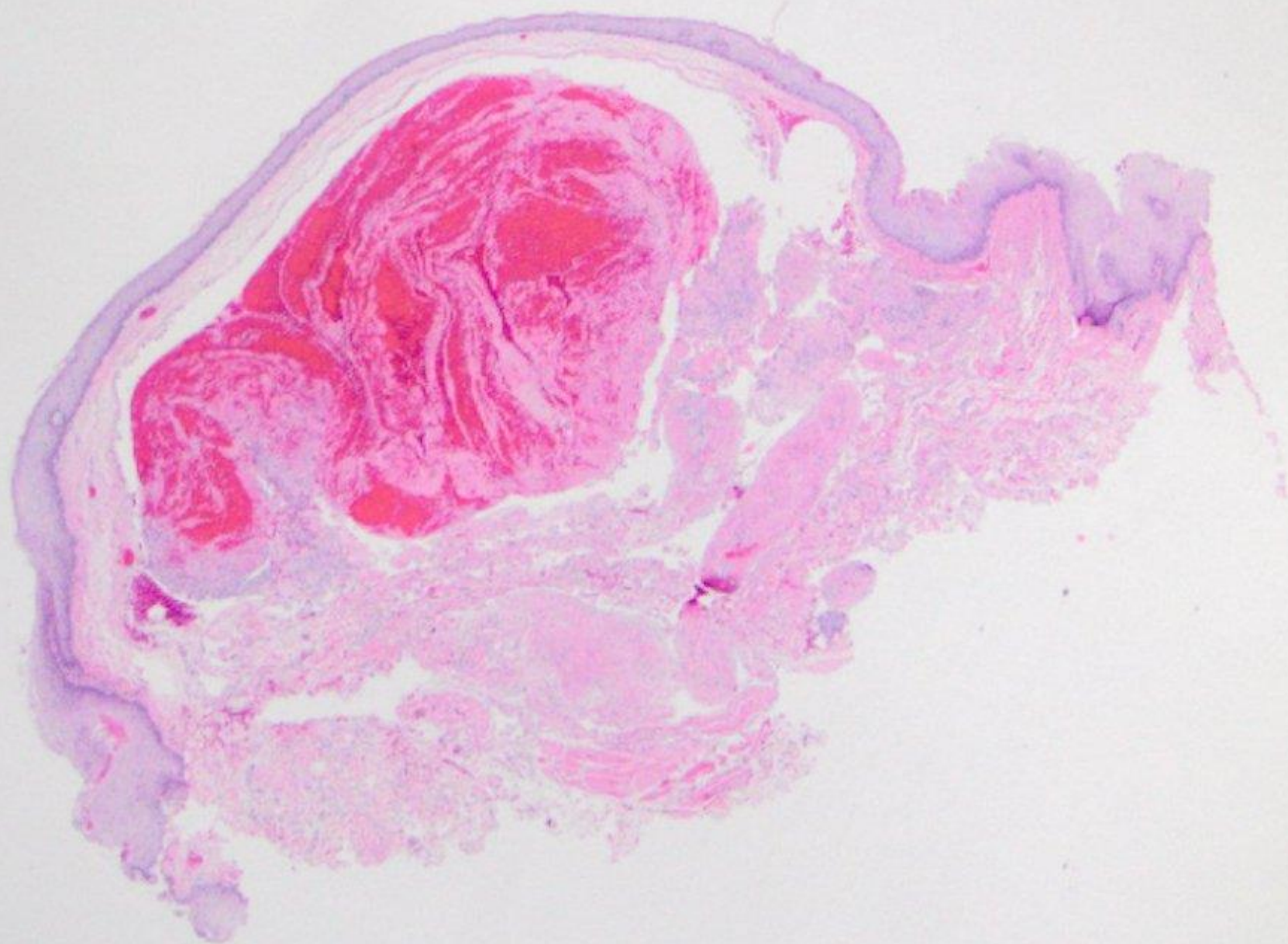
Diplomate, American Board of General Dentistry

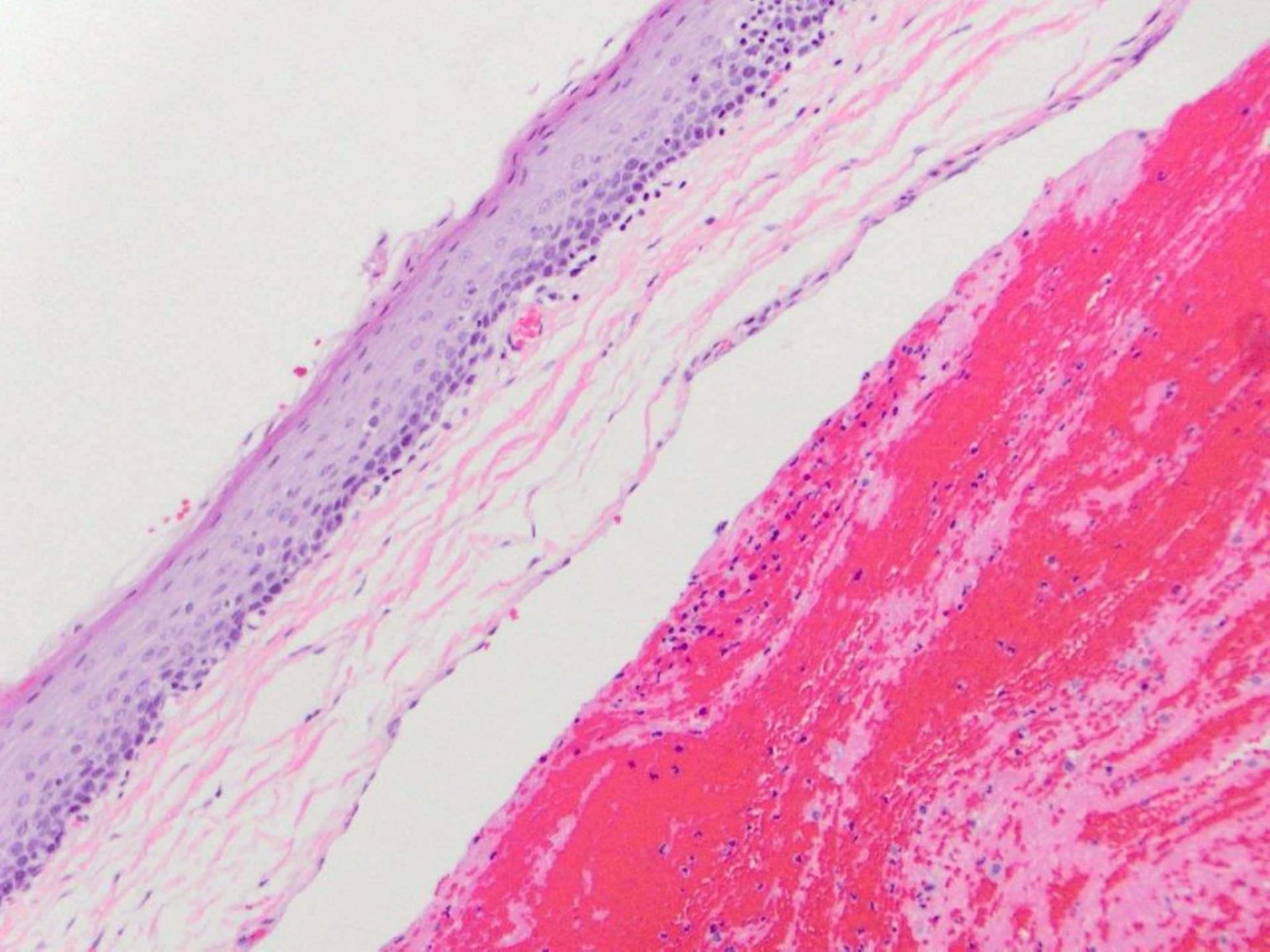


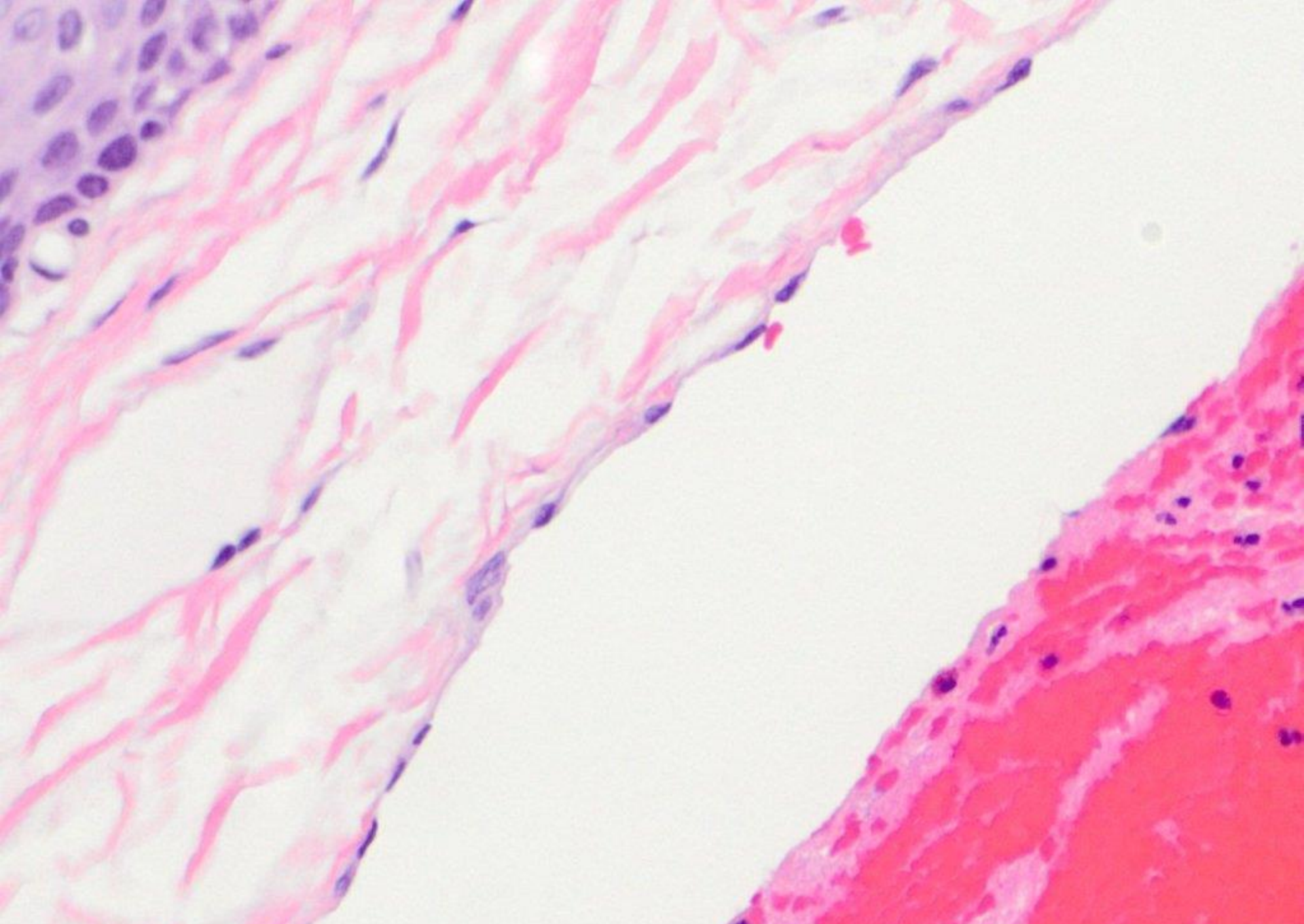
squamous papilloma



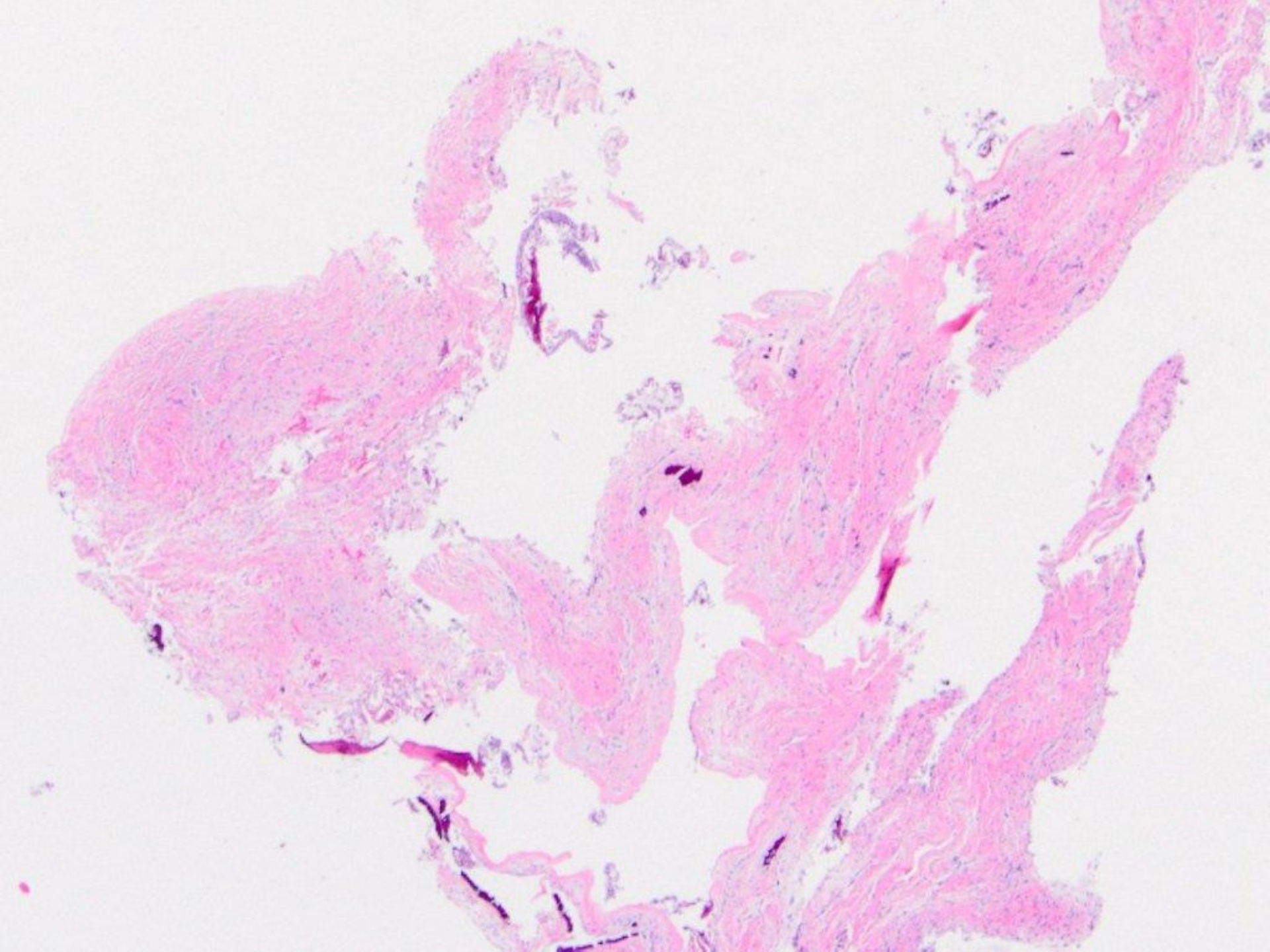
squamous papilloma

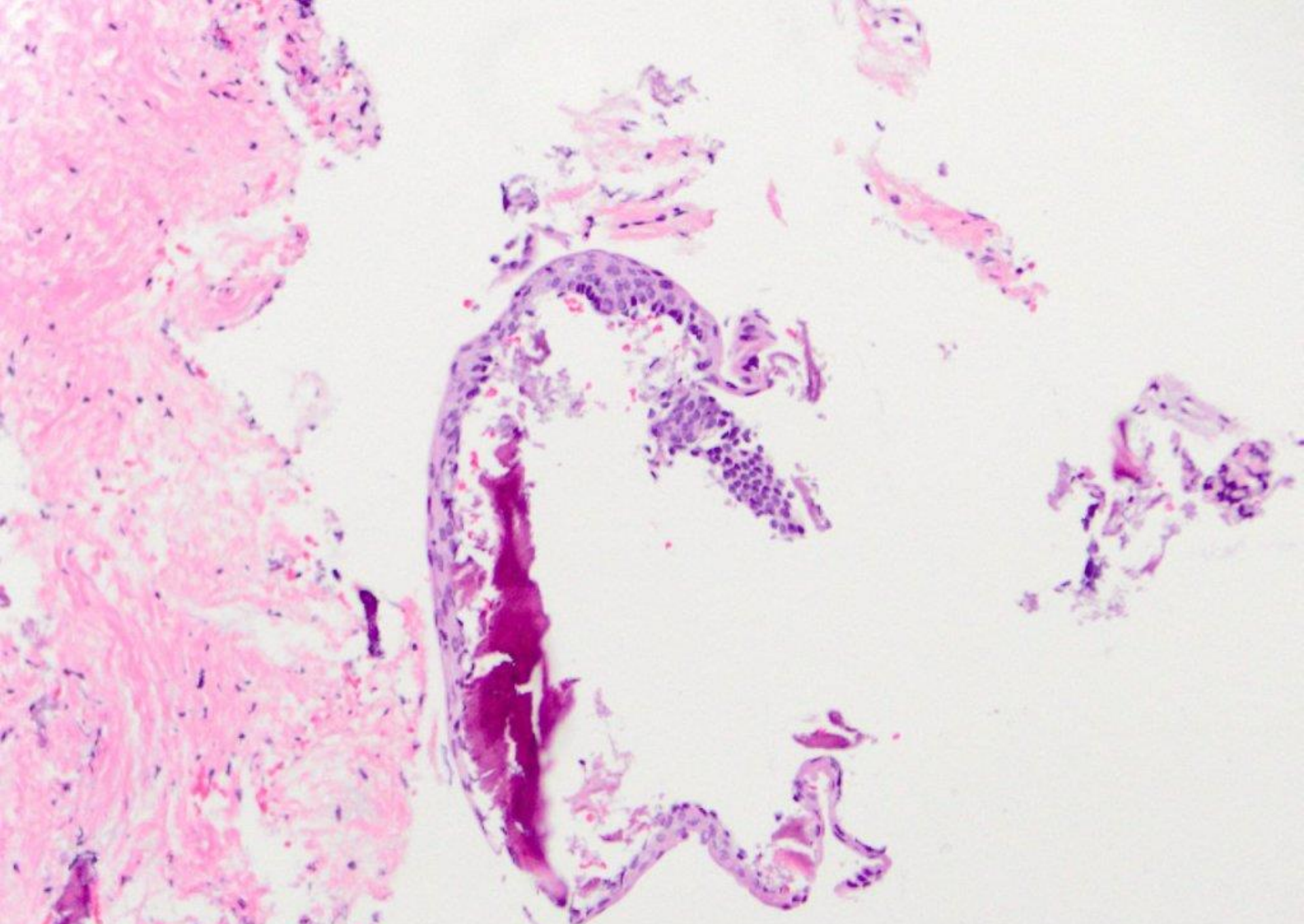




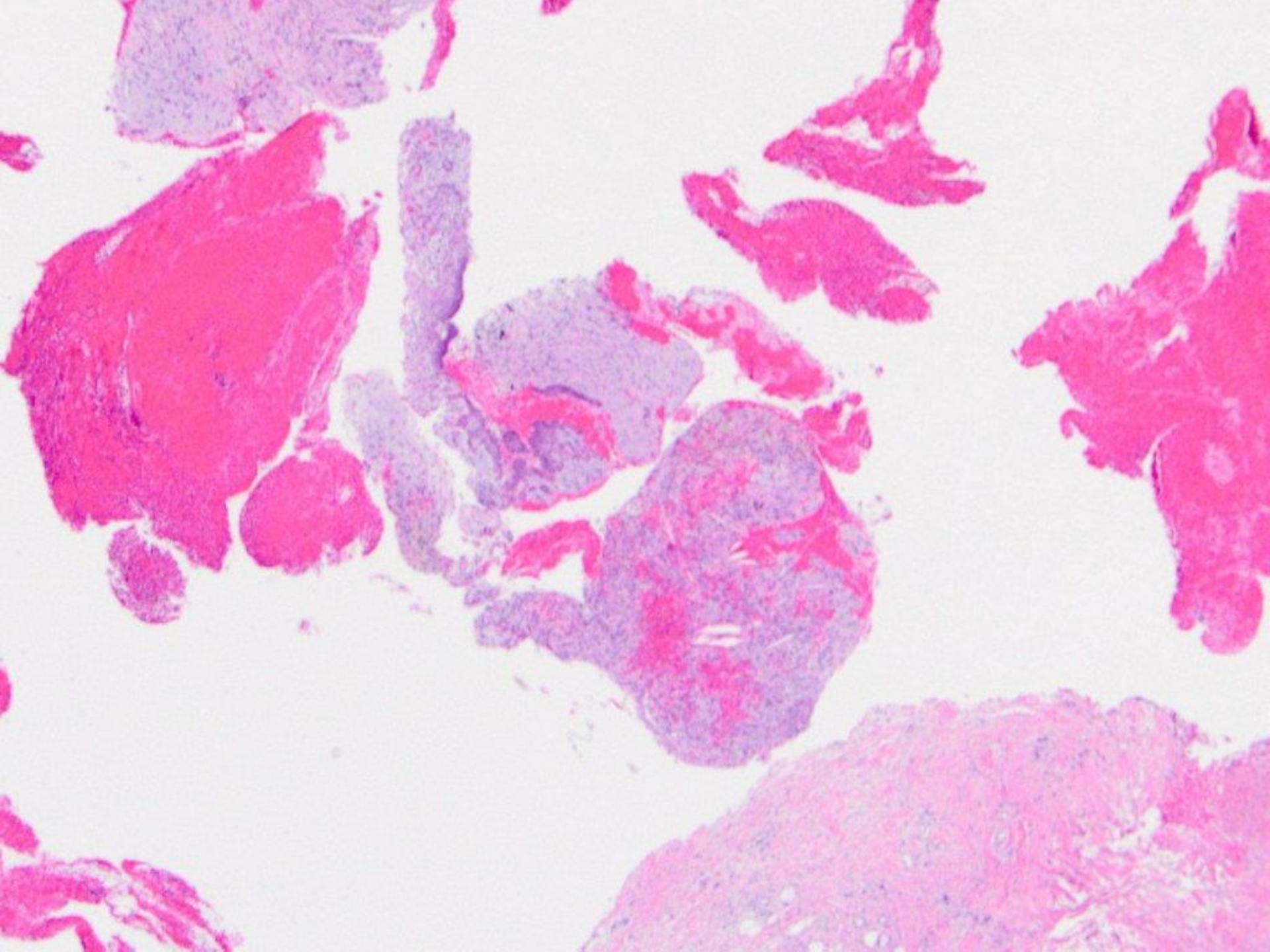


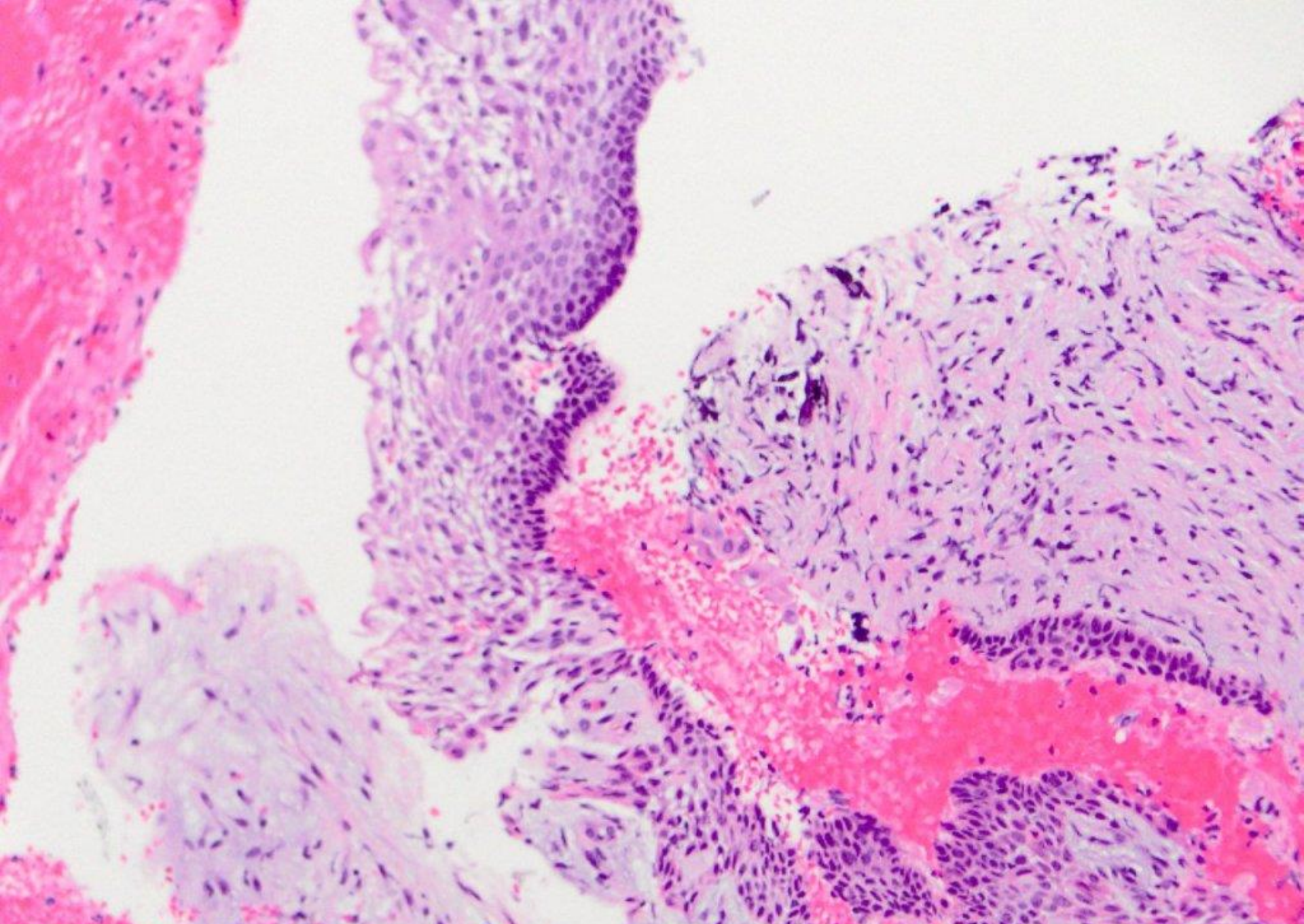
varix with organizing thrombus



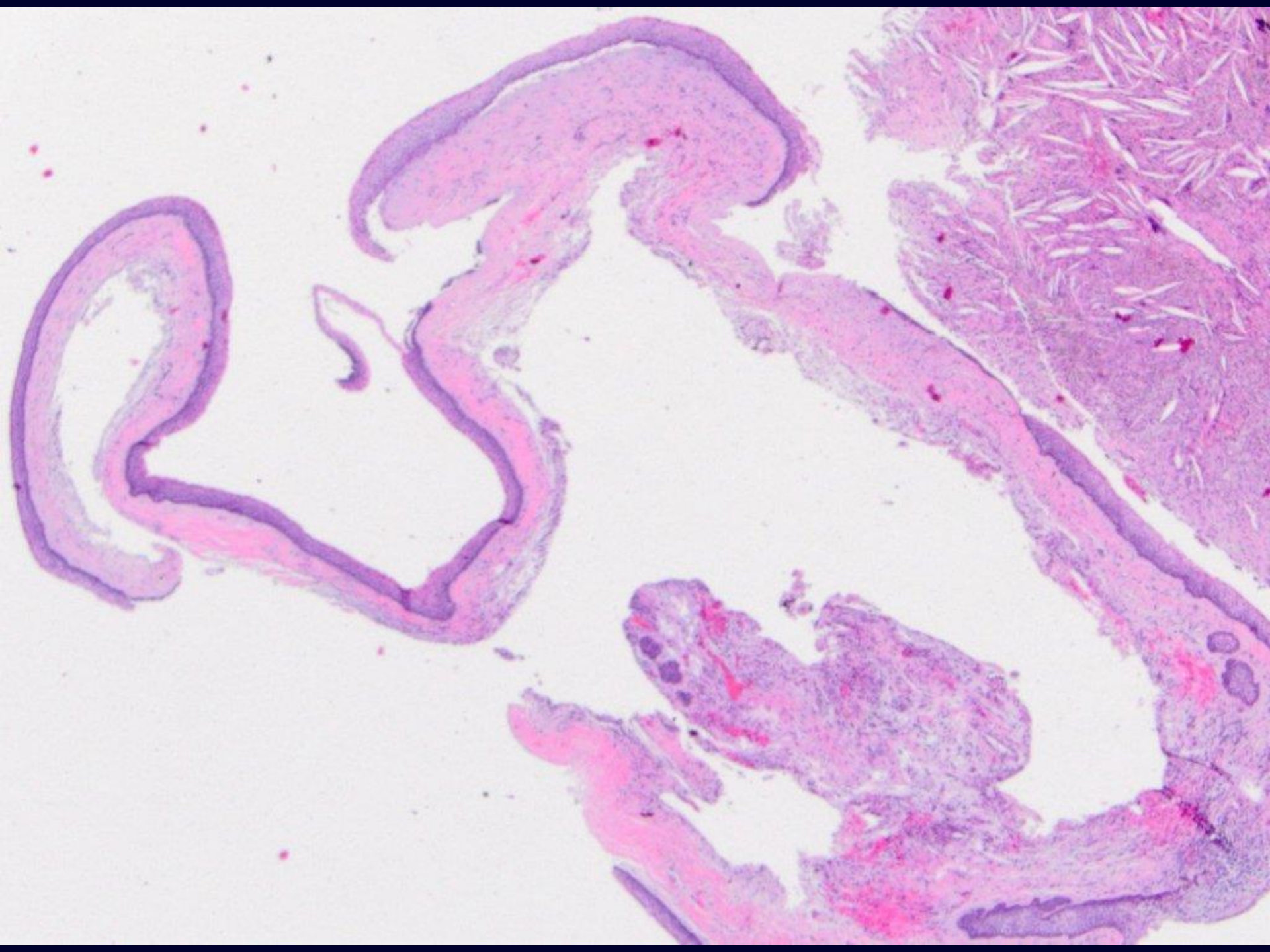


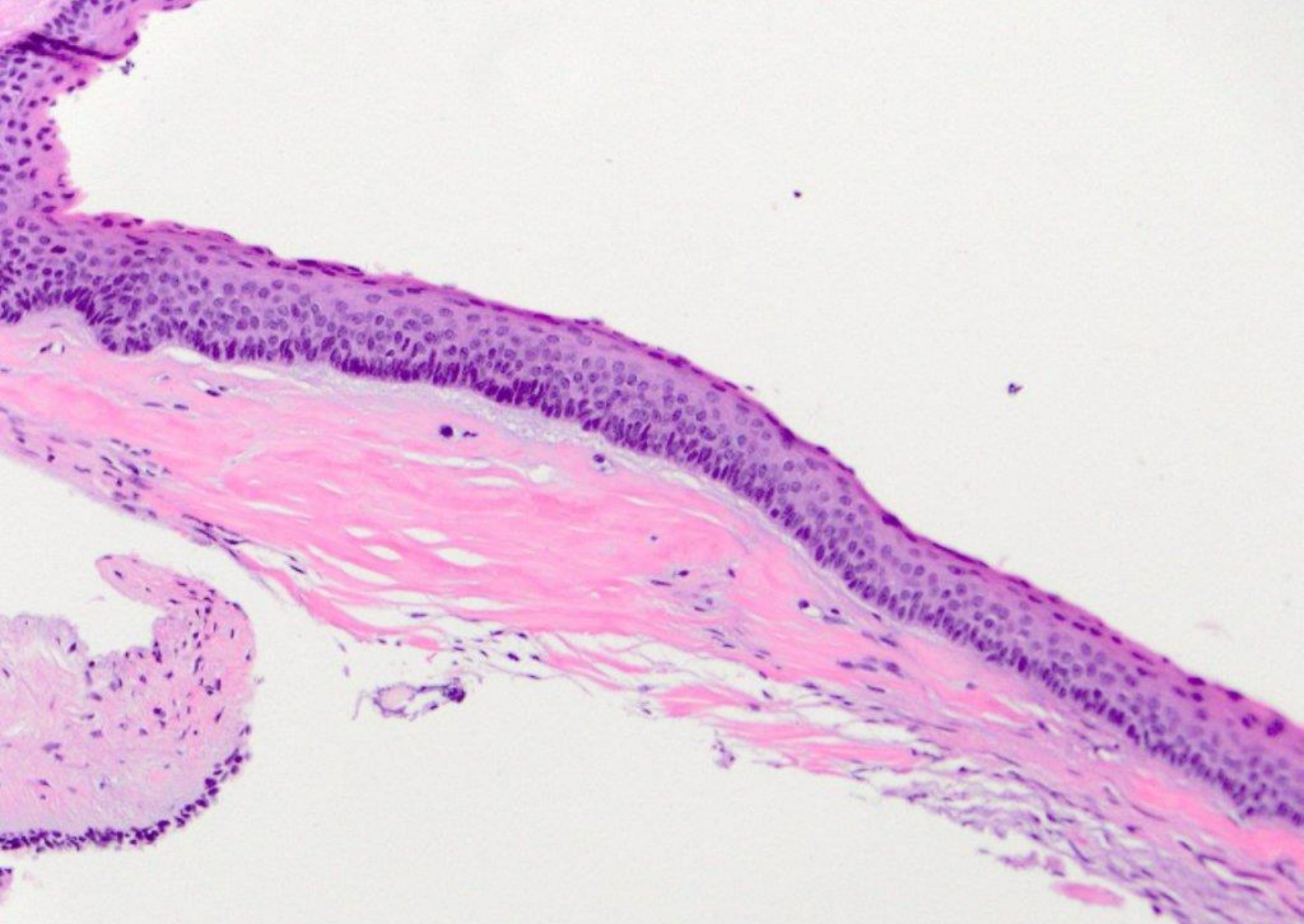
lateral periodontal cyst [RL lateral to #30/apical to #T which was retained, #29 missing]



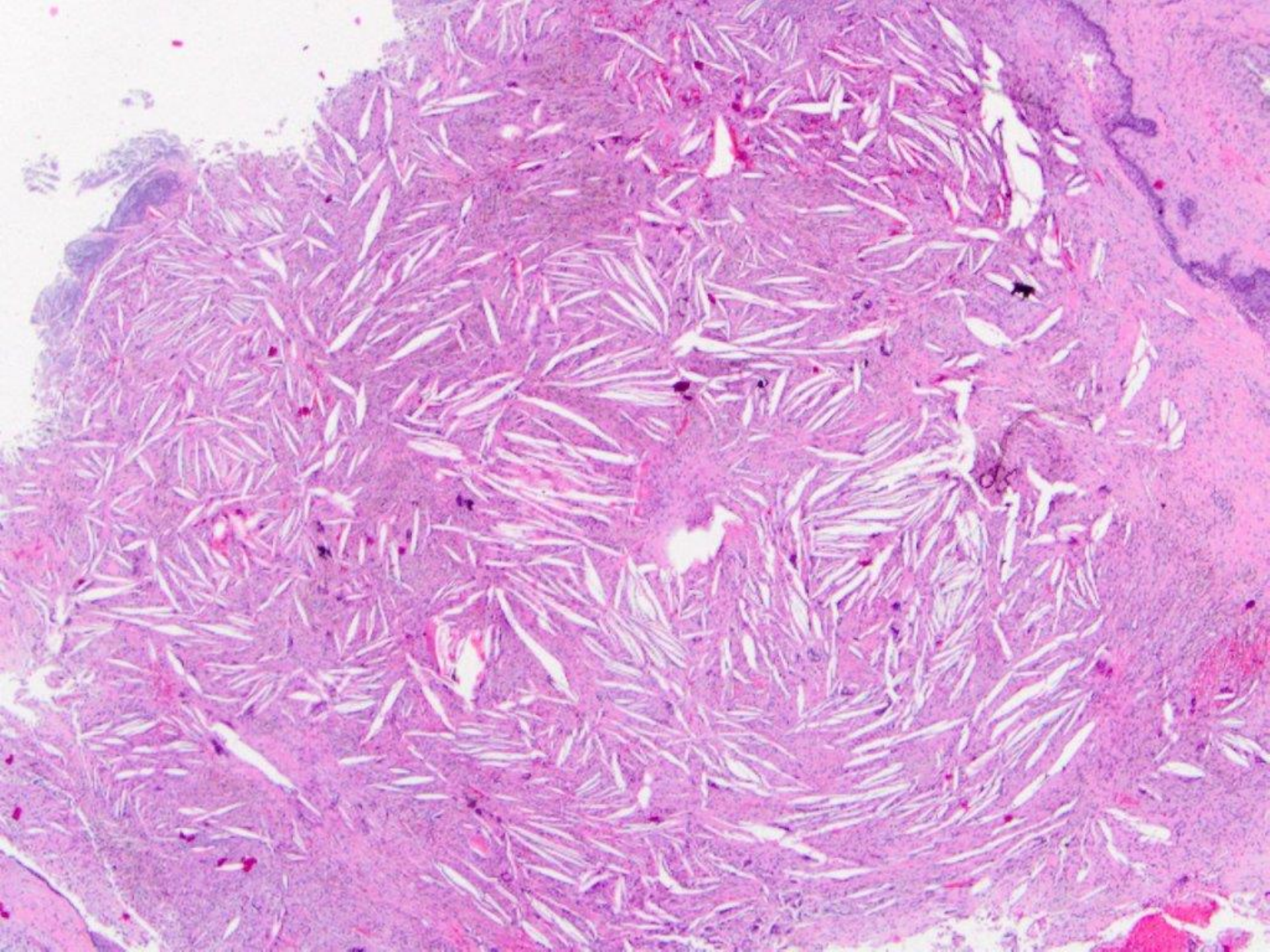


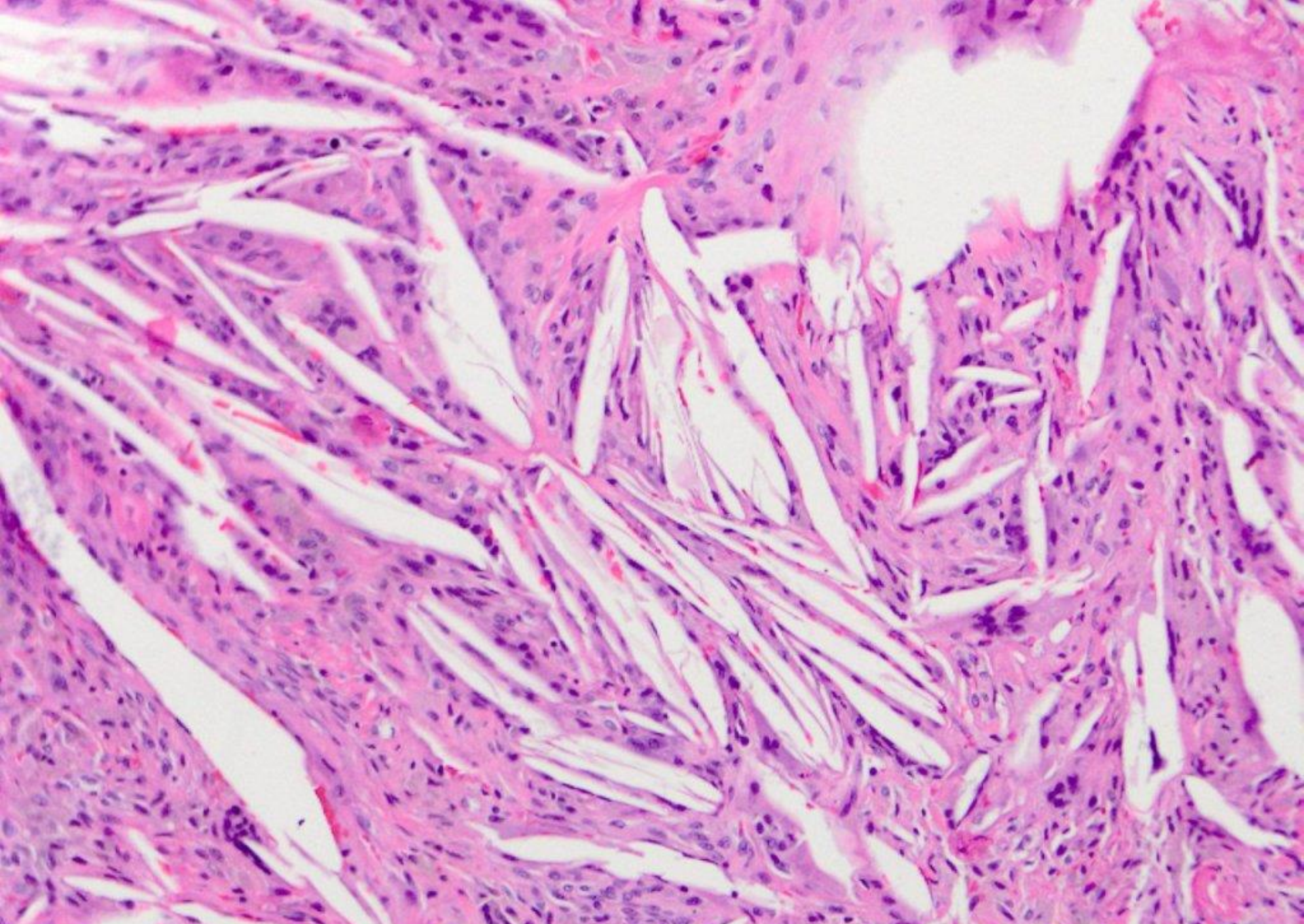
biopsy of mandibular radiolucency, s/o ameloblastoma



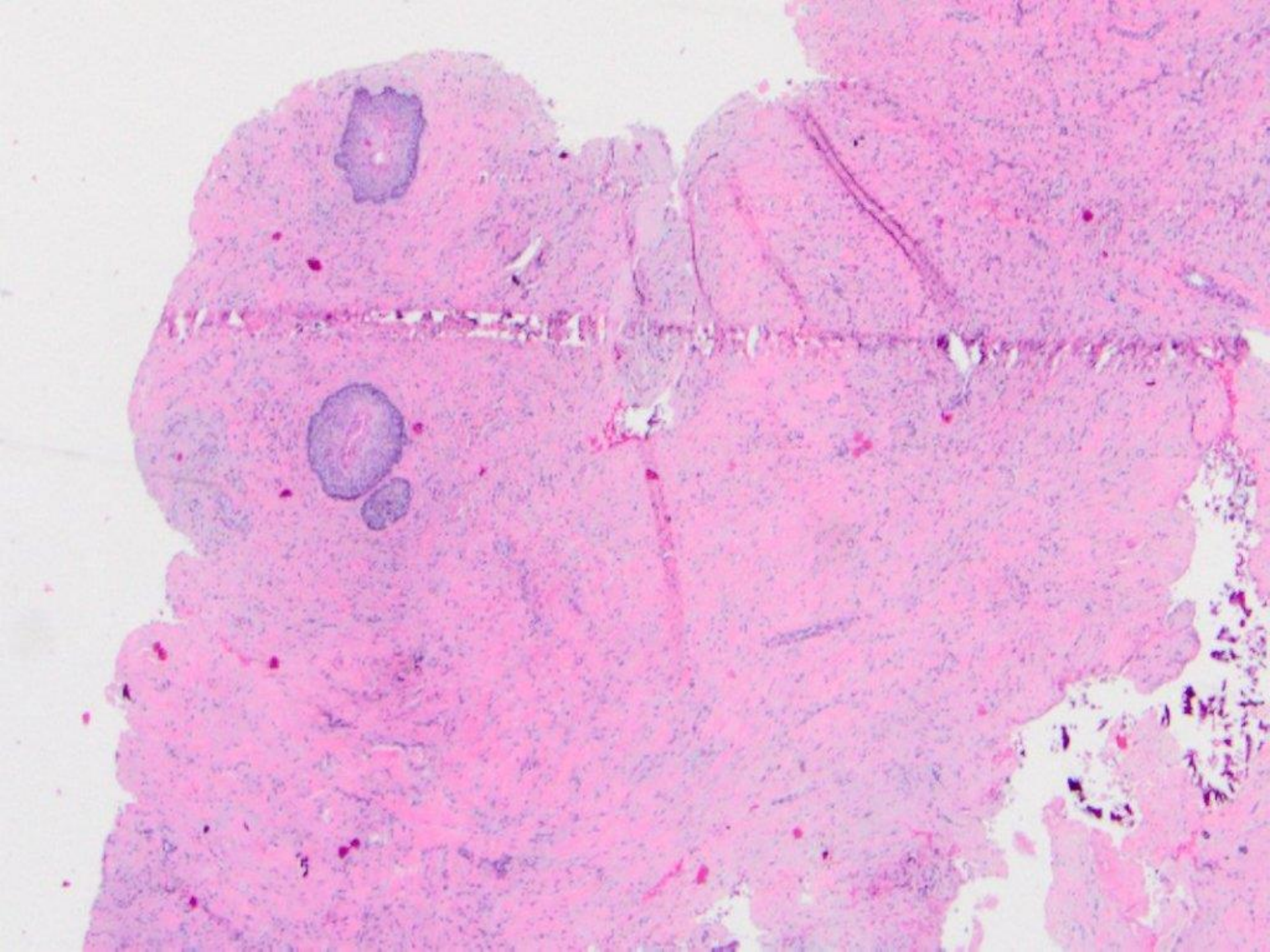


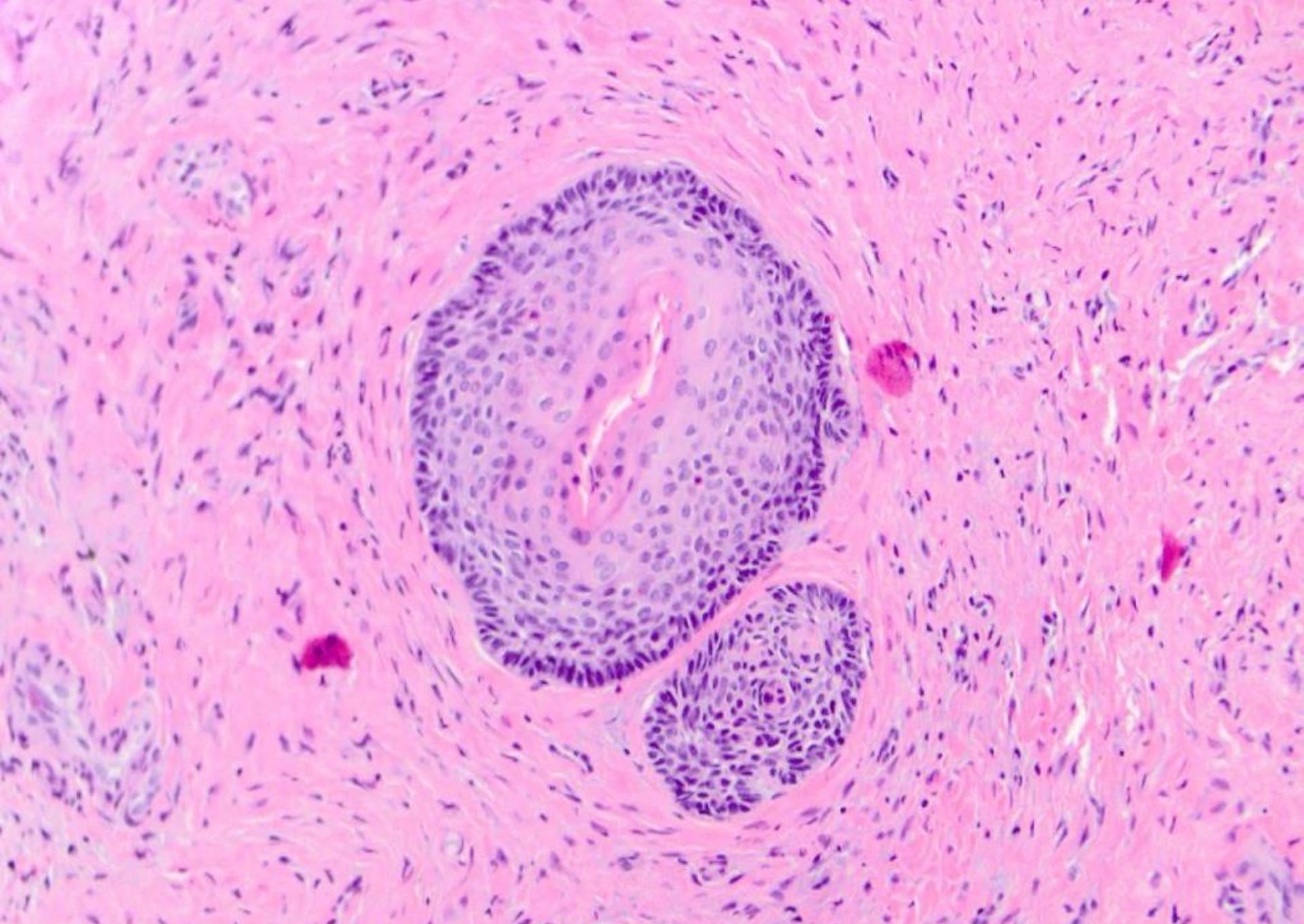
excision of mandibular radiolucency, DX odontogenic keratocyst... but...



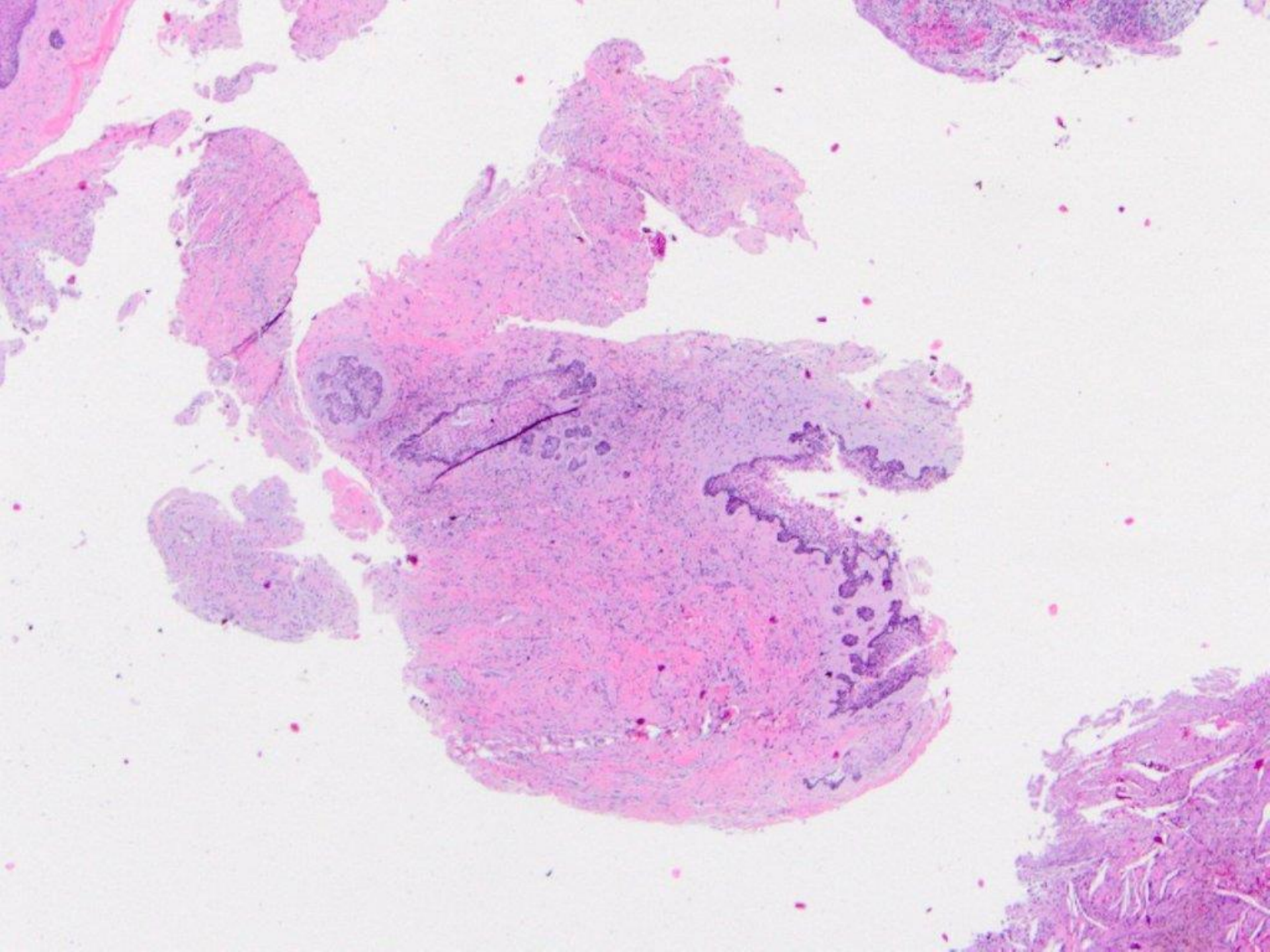


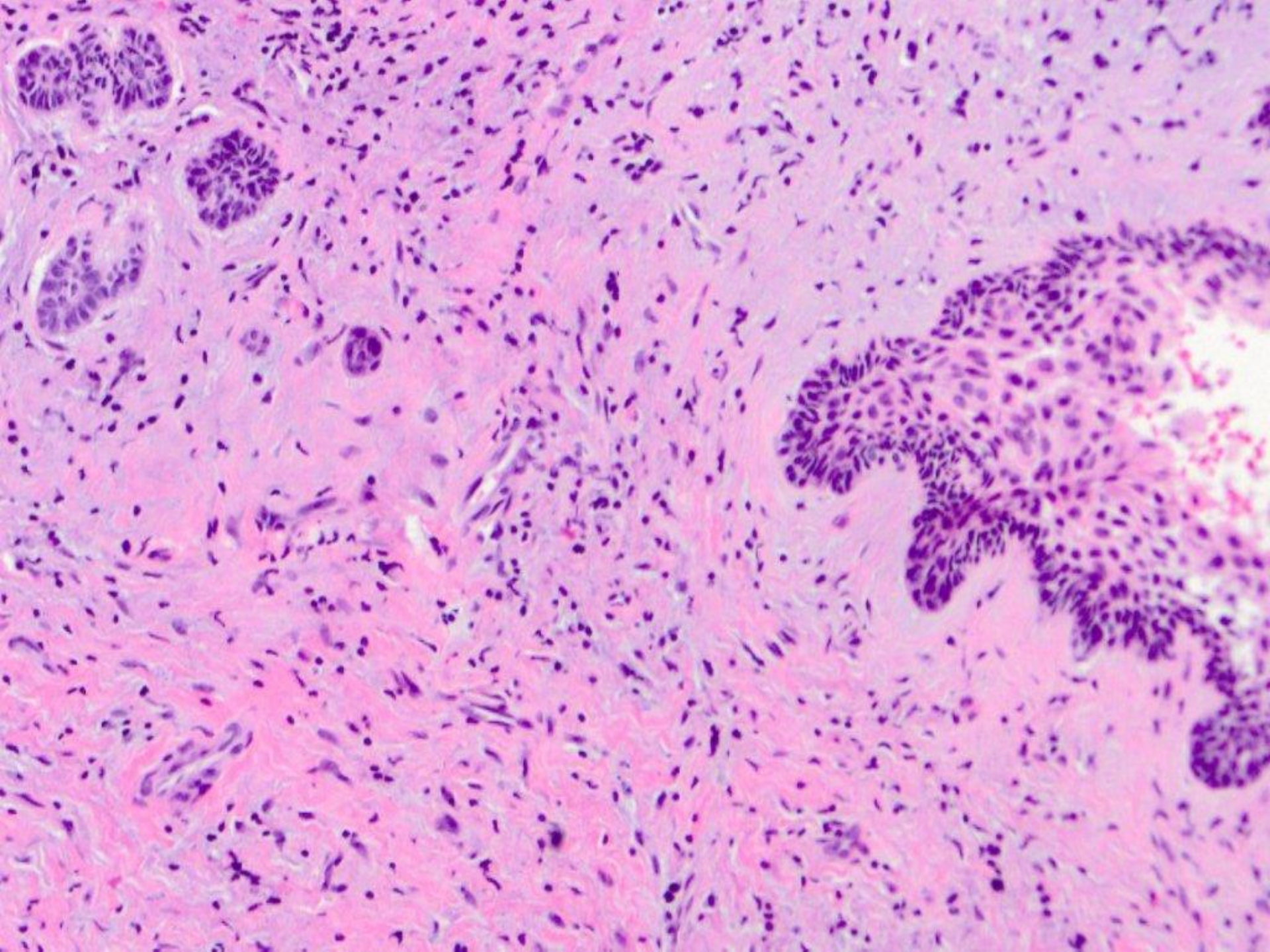
cholesterol clefts, and...

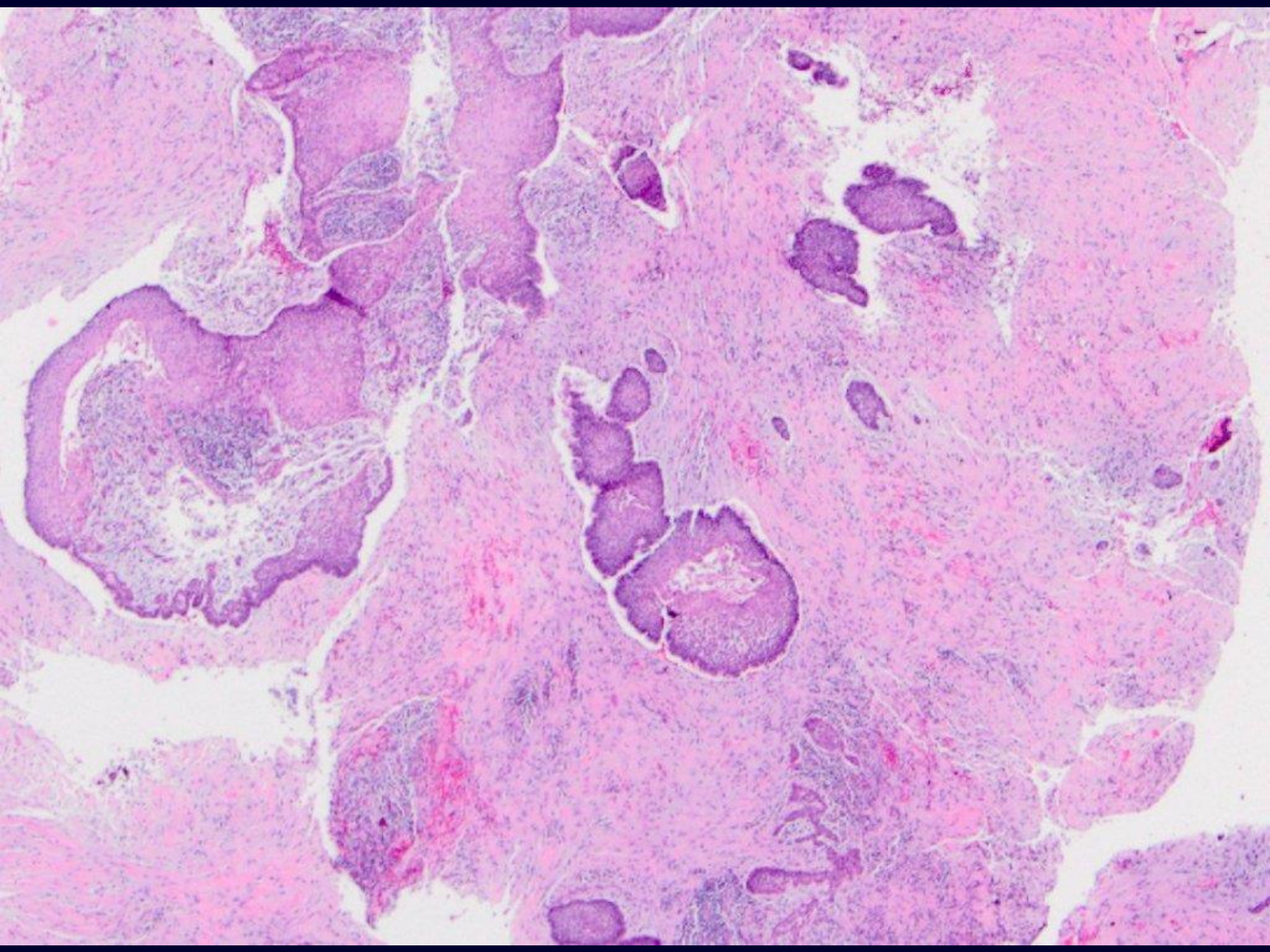


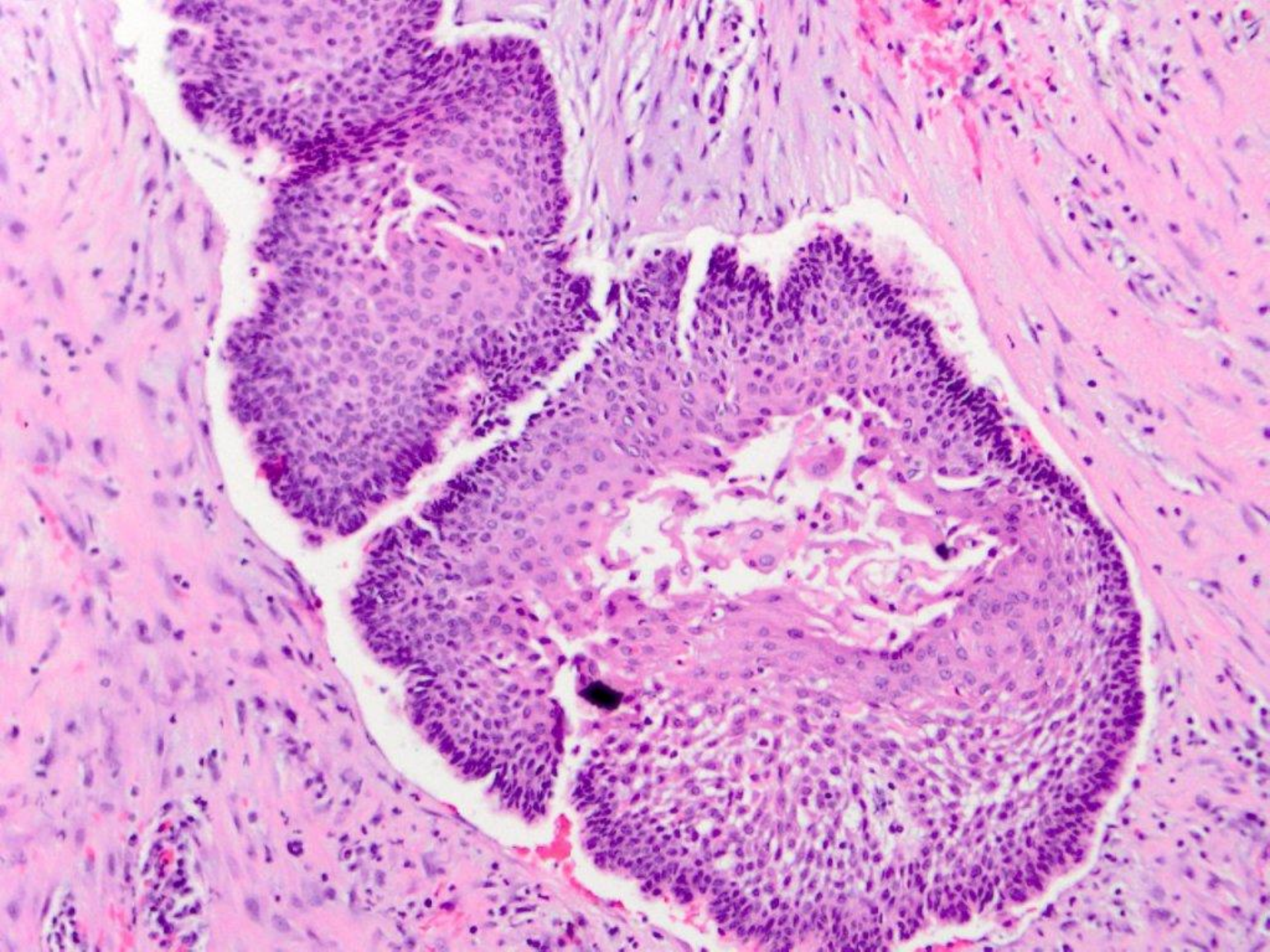


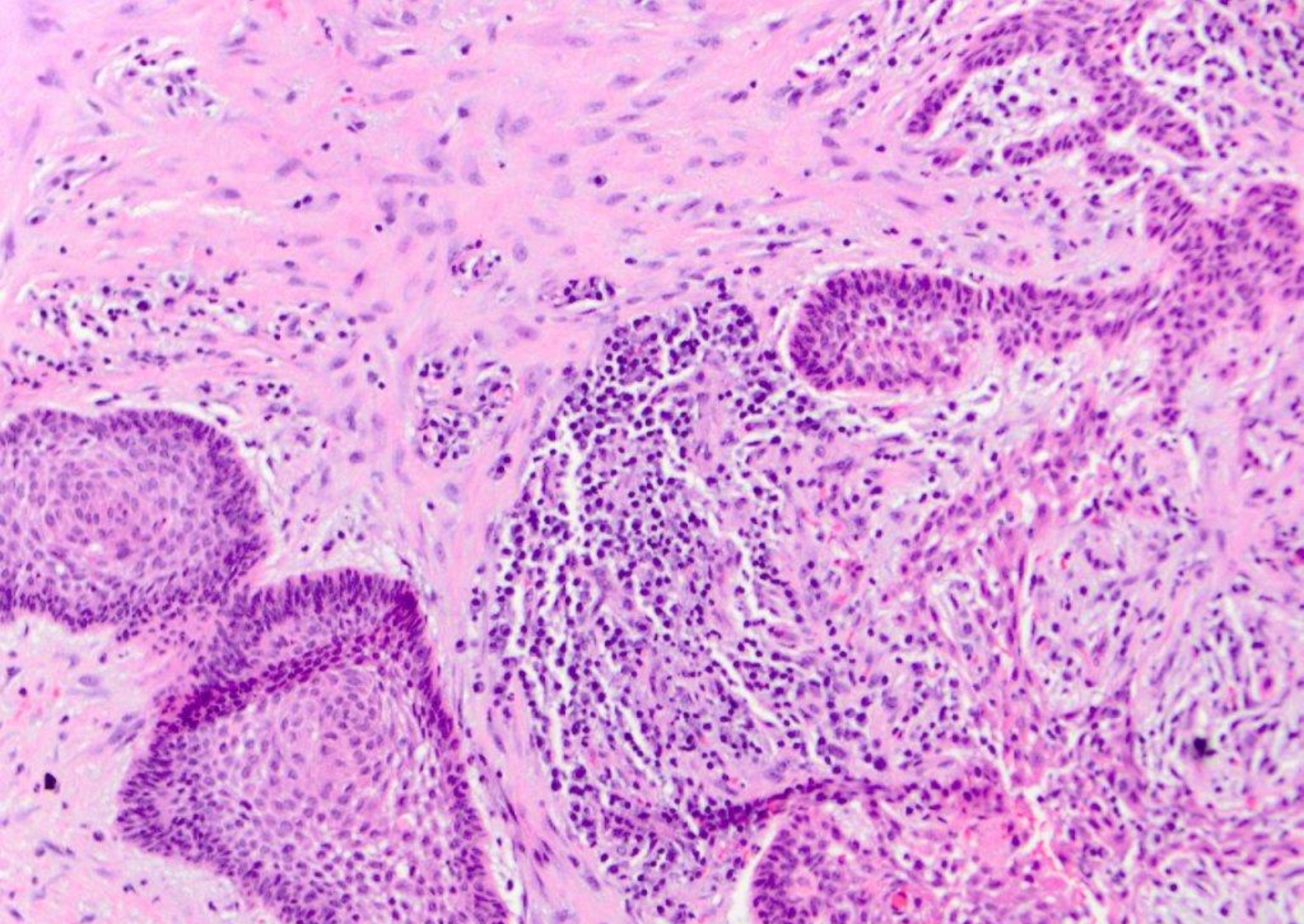
satellite cysts, and...



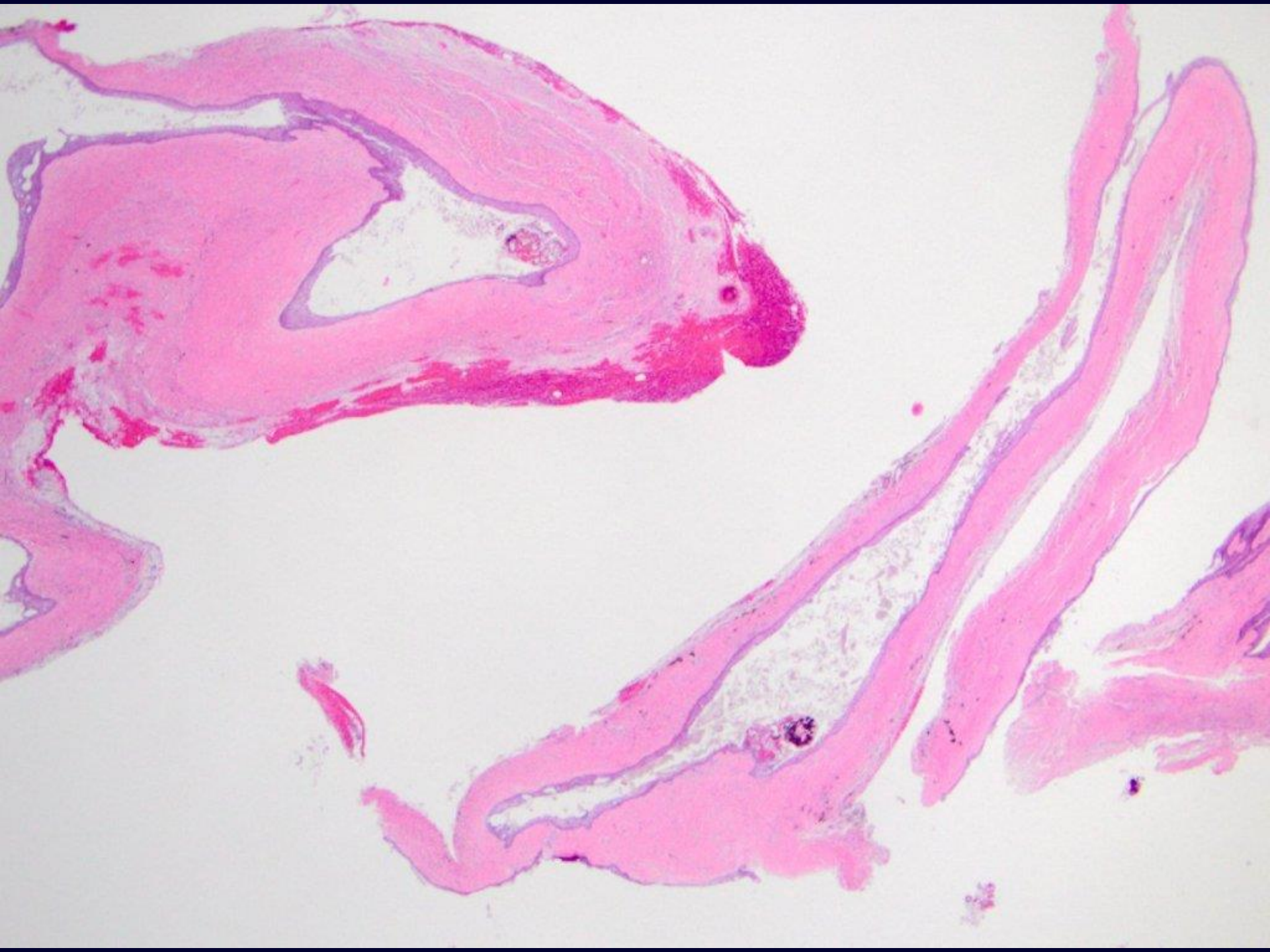


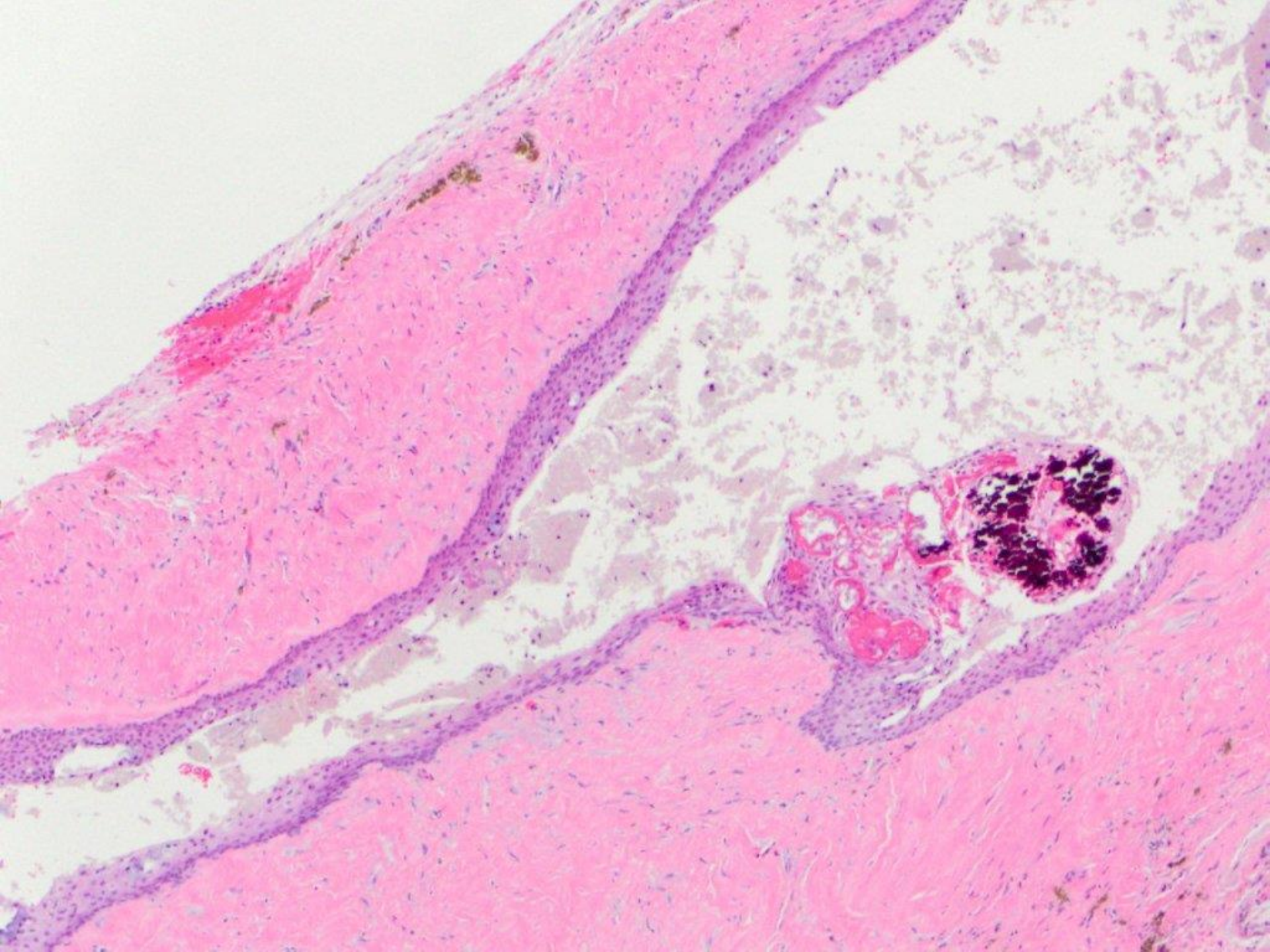


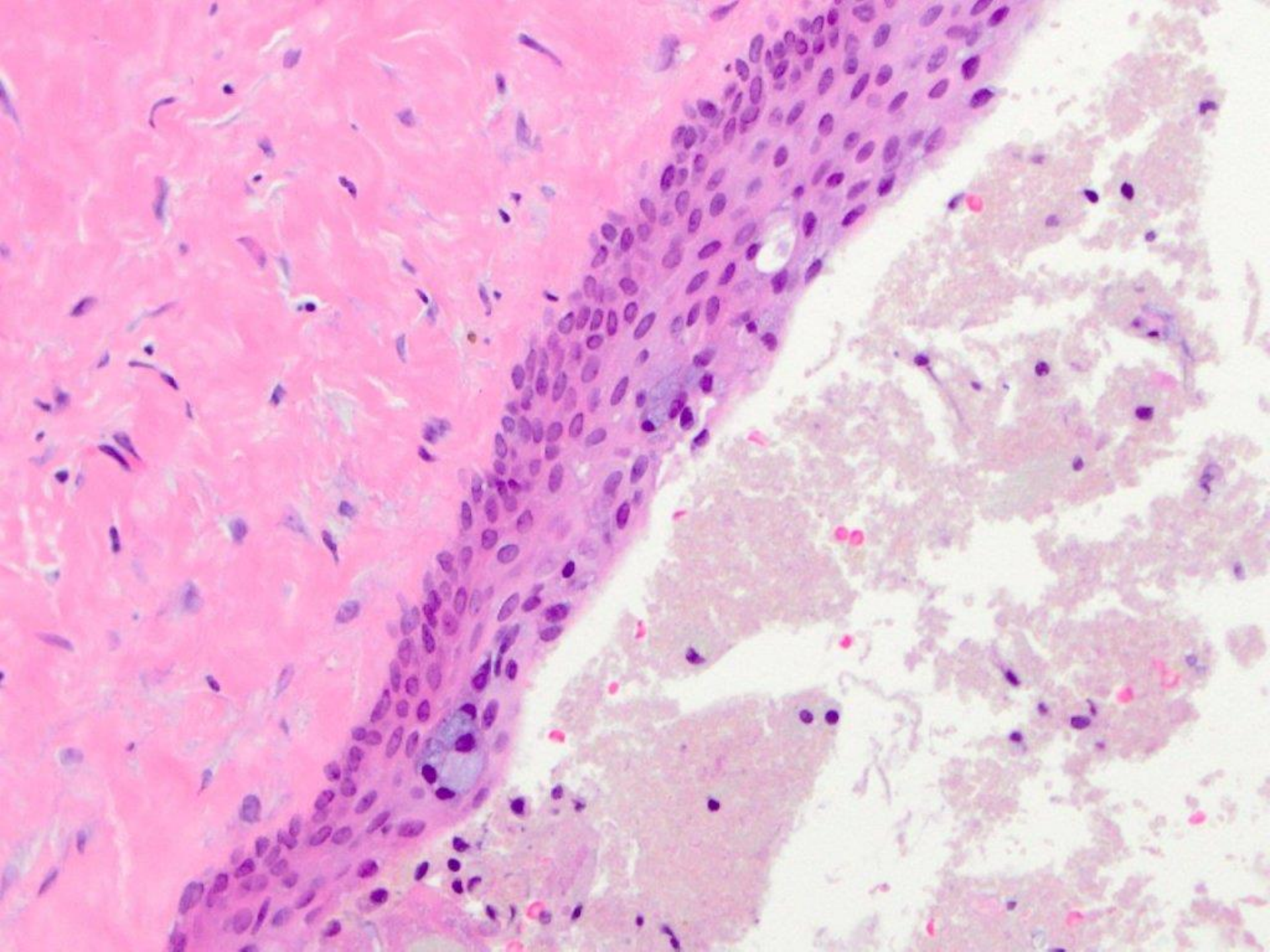


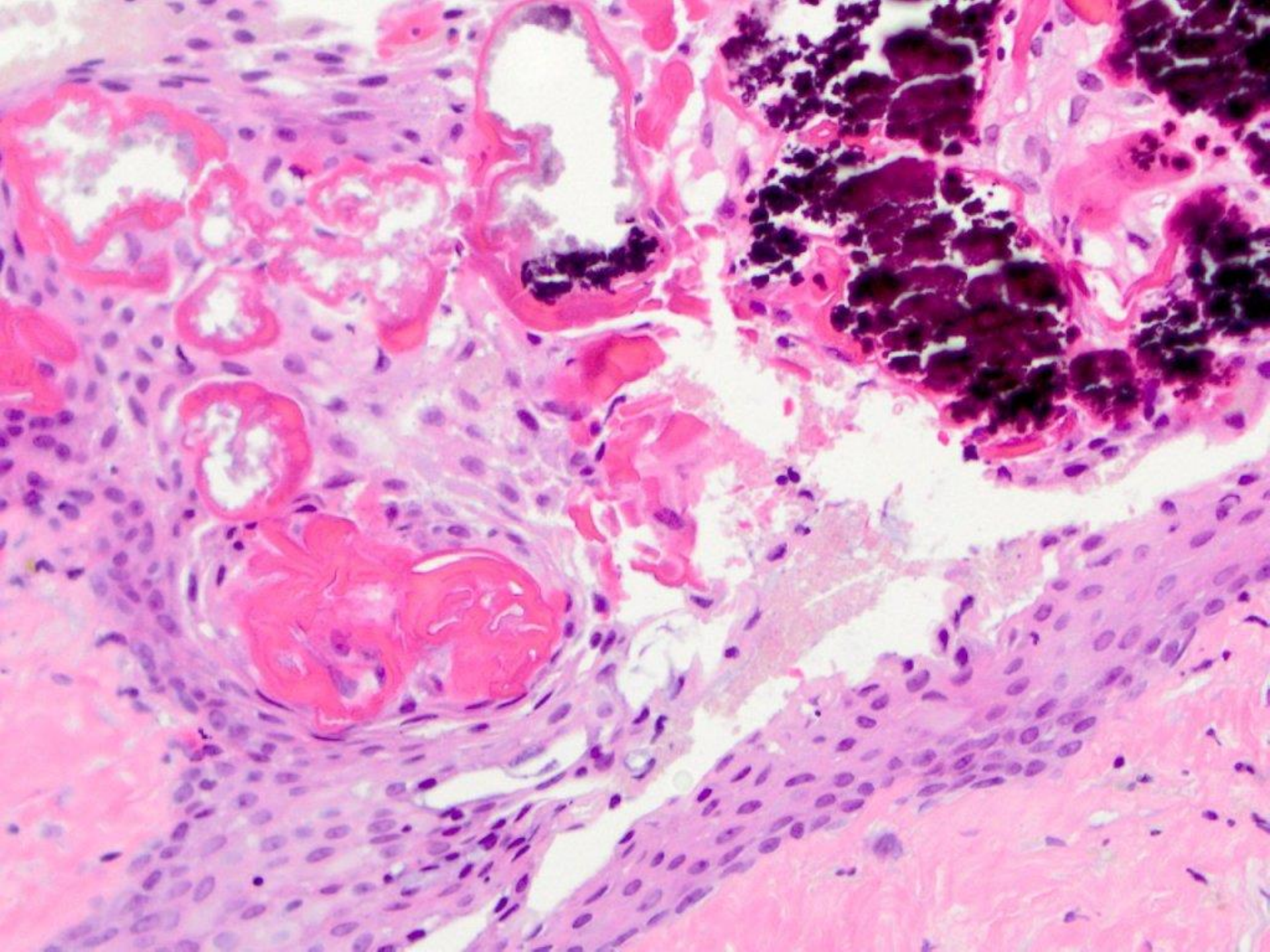


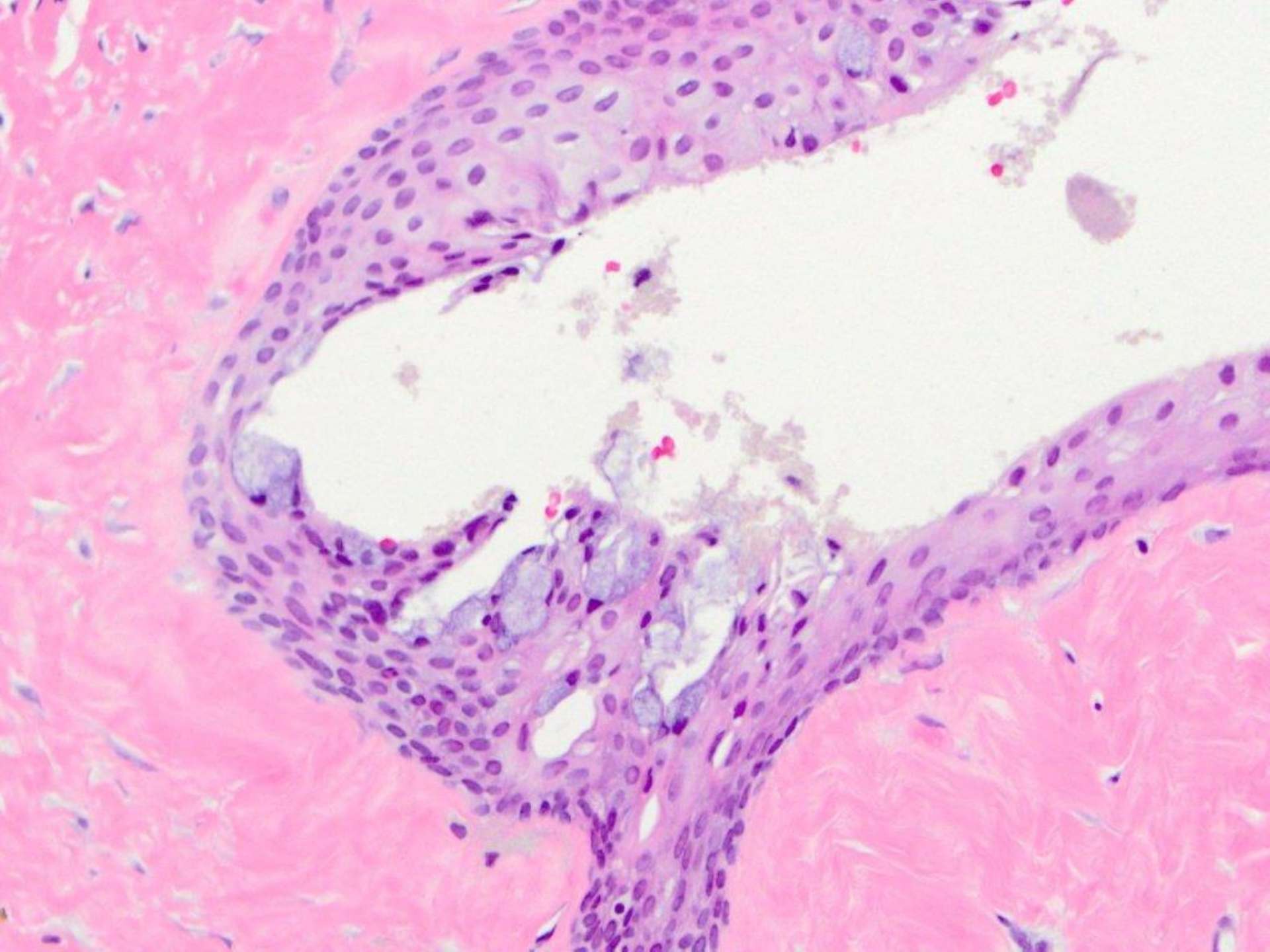
areas of ameloblastoma within the cyst wall!

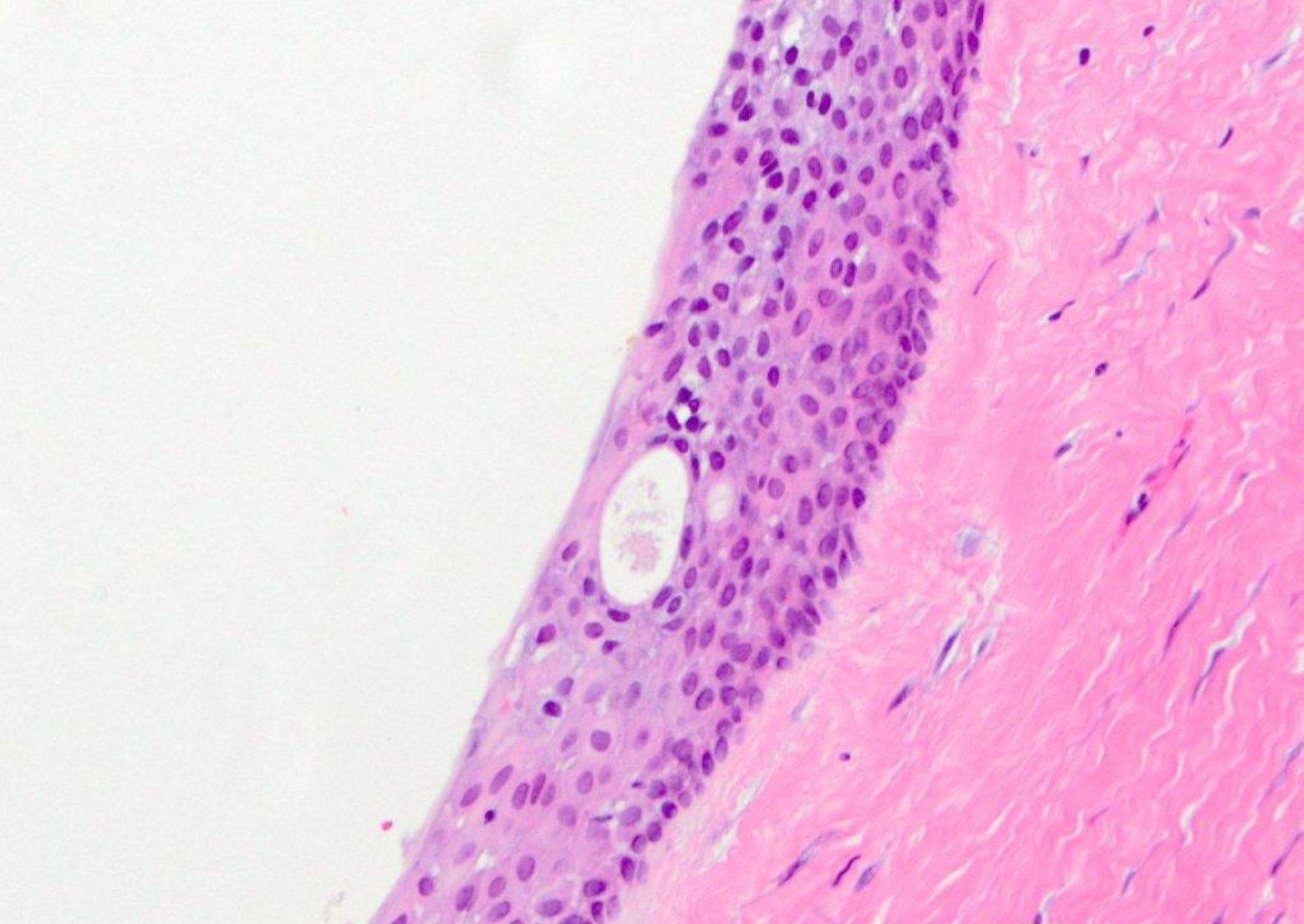




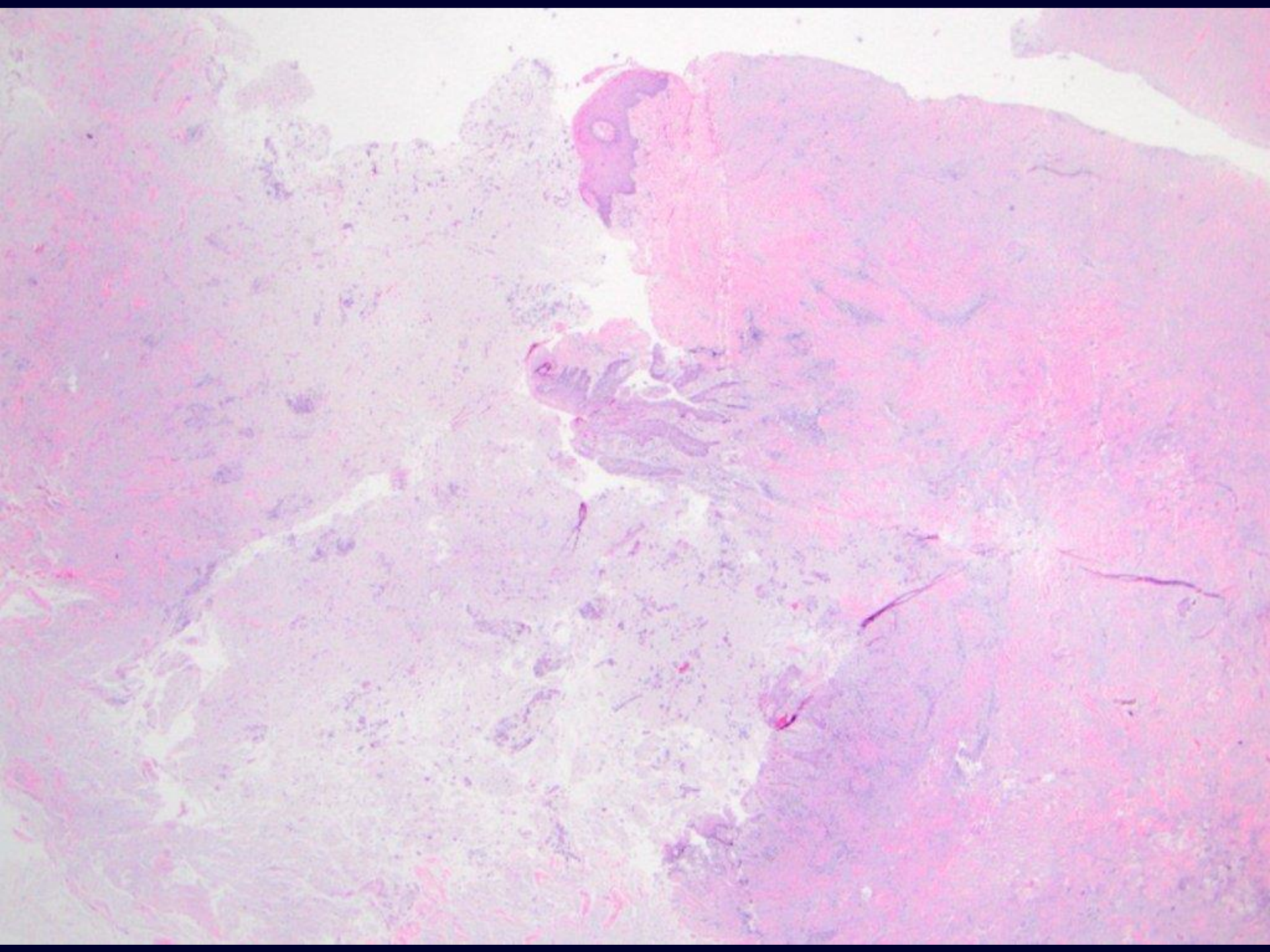


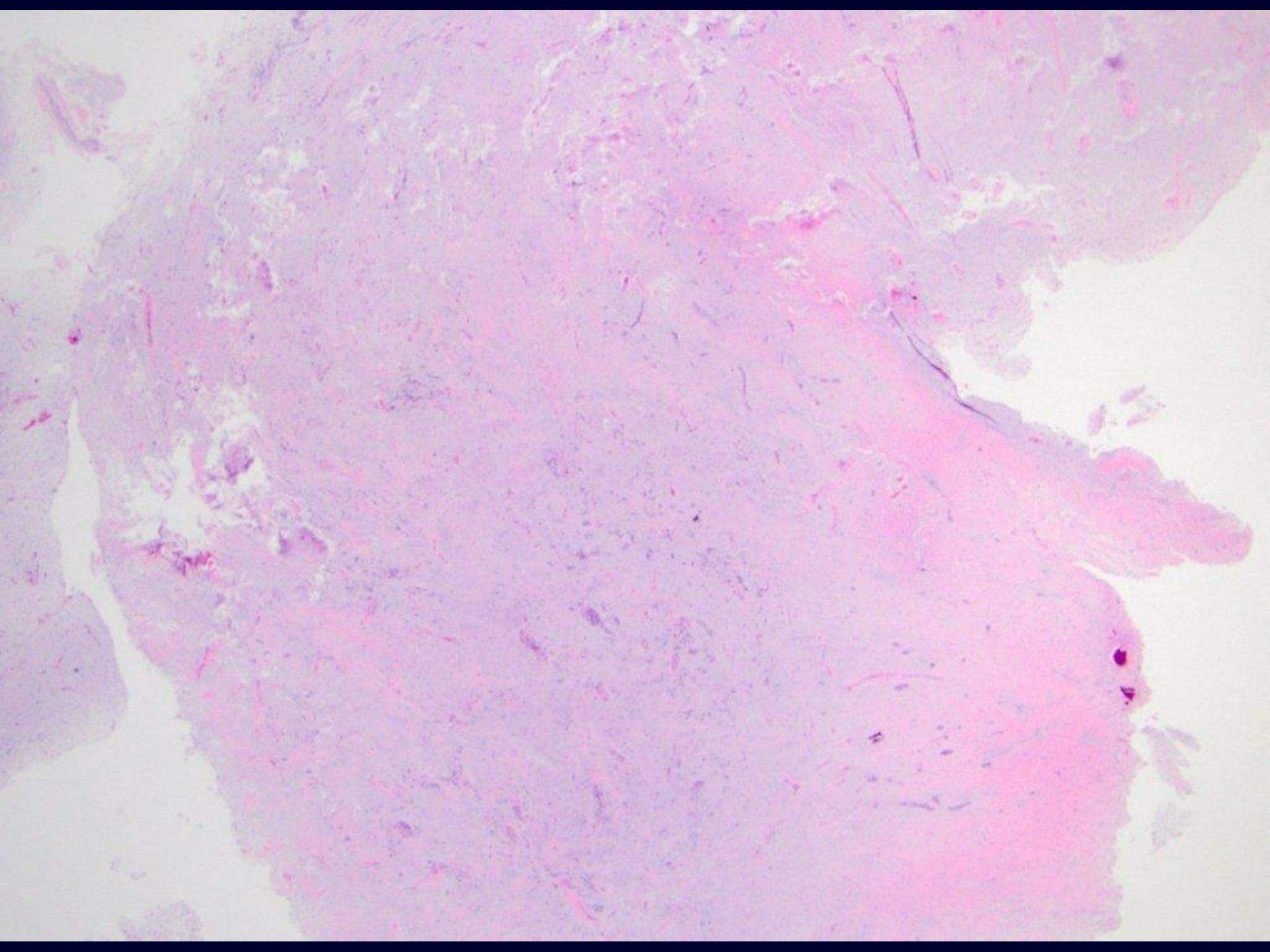


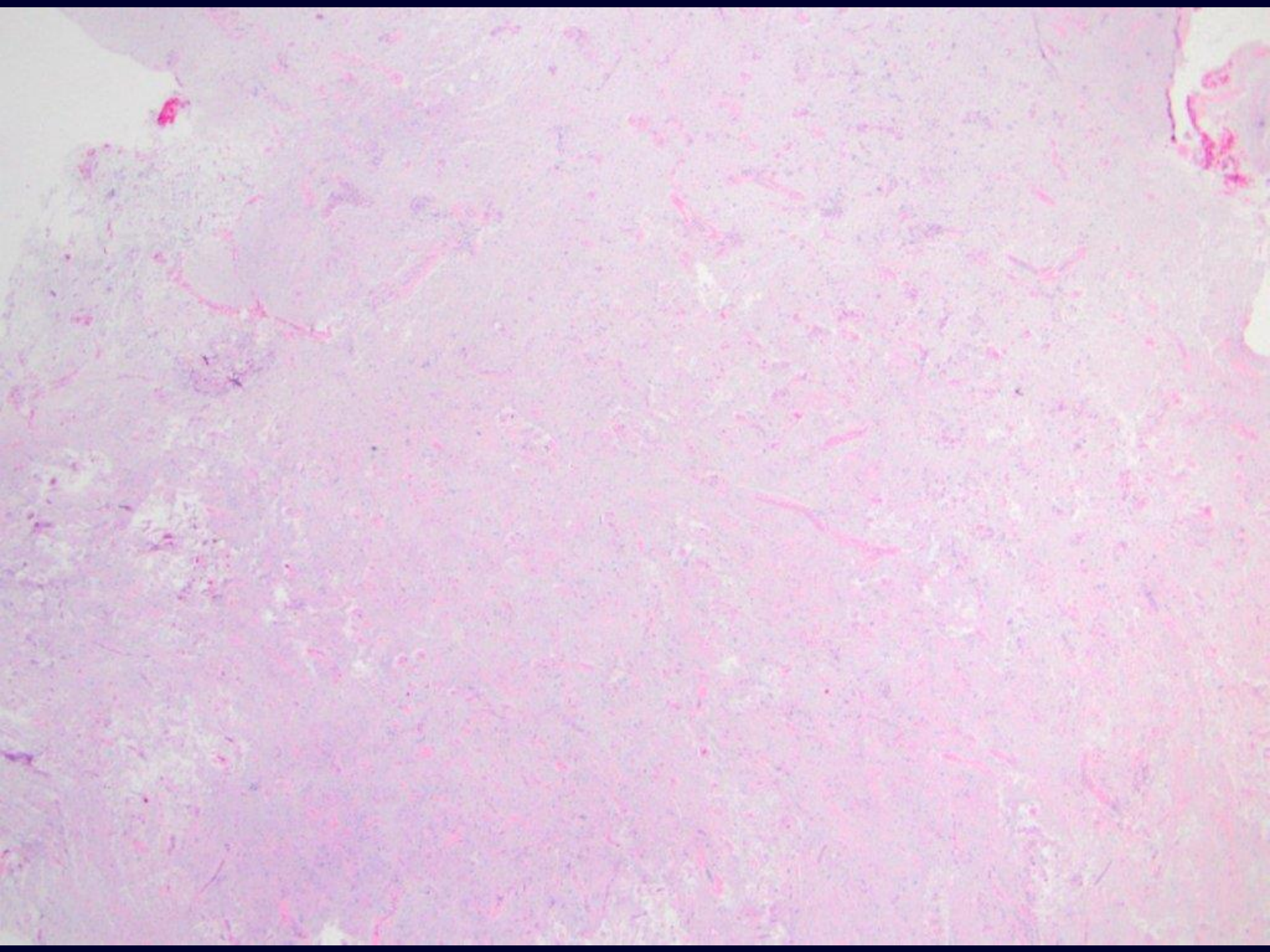


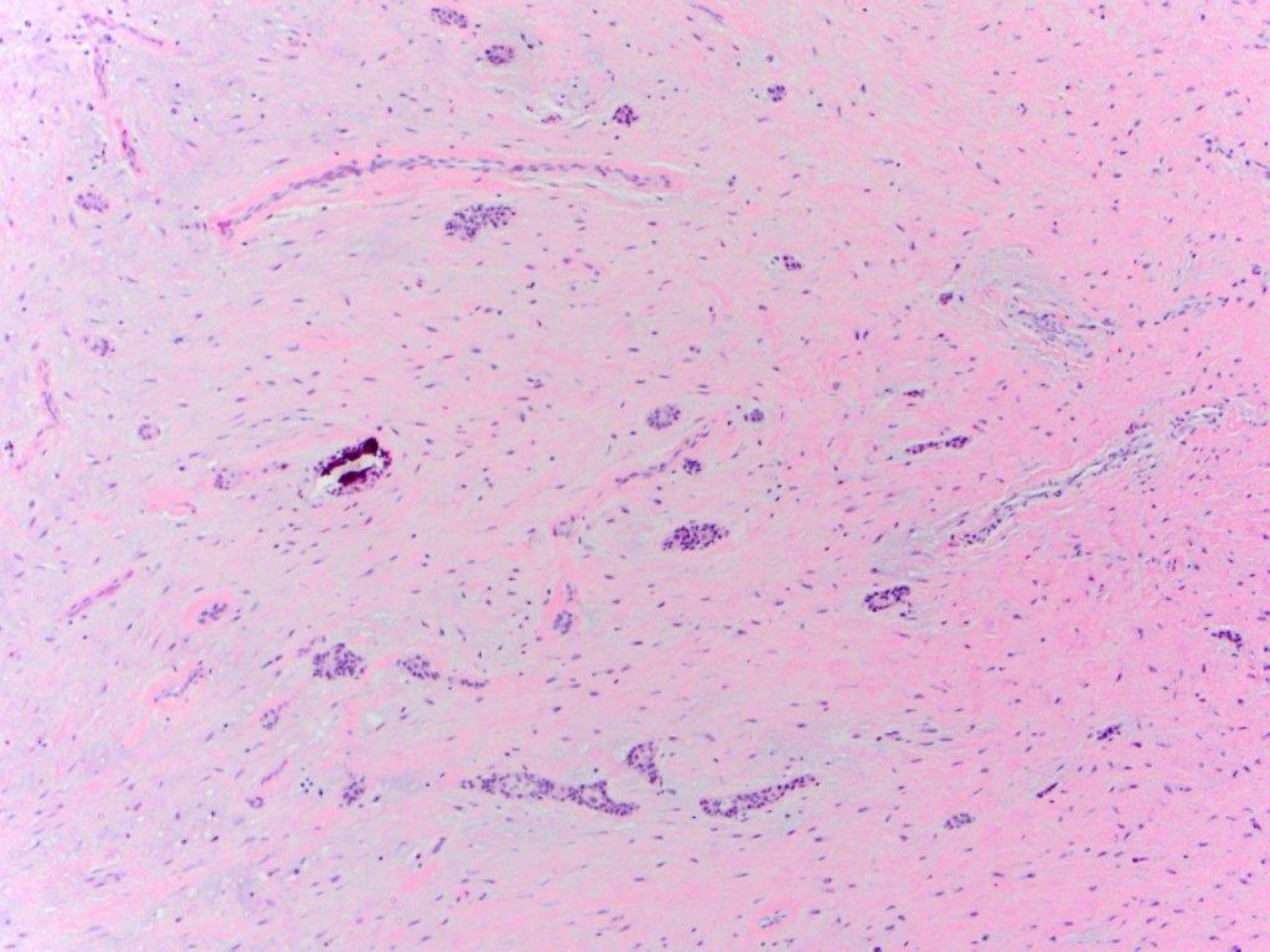


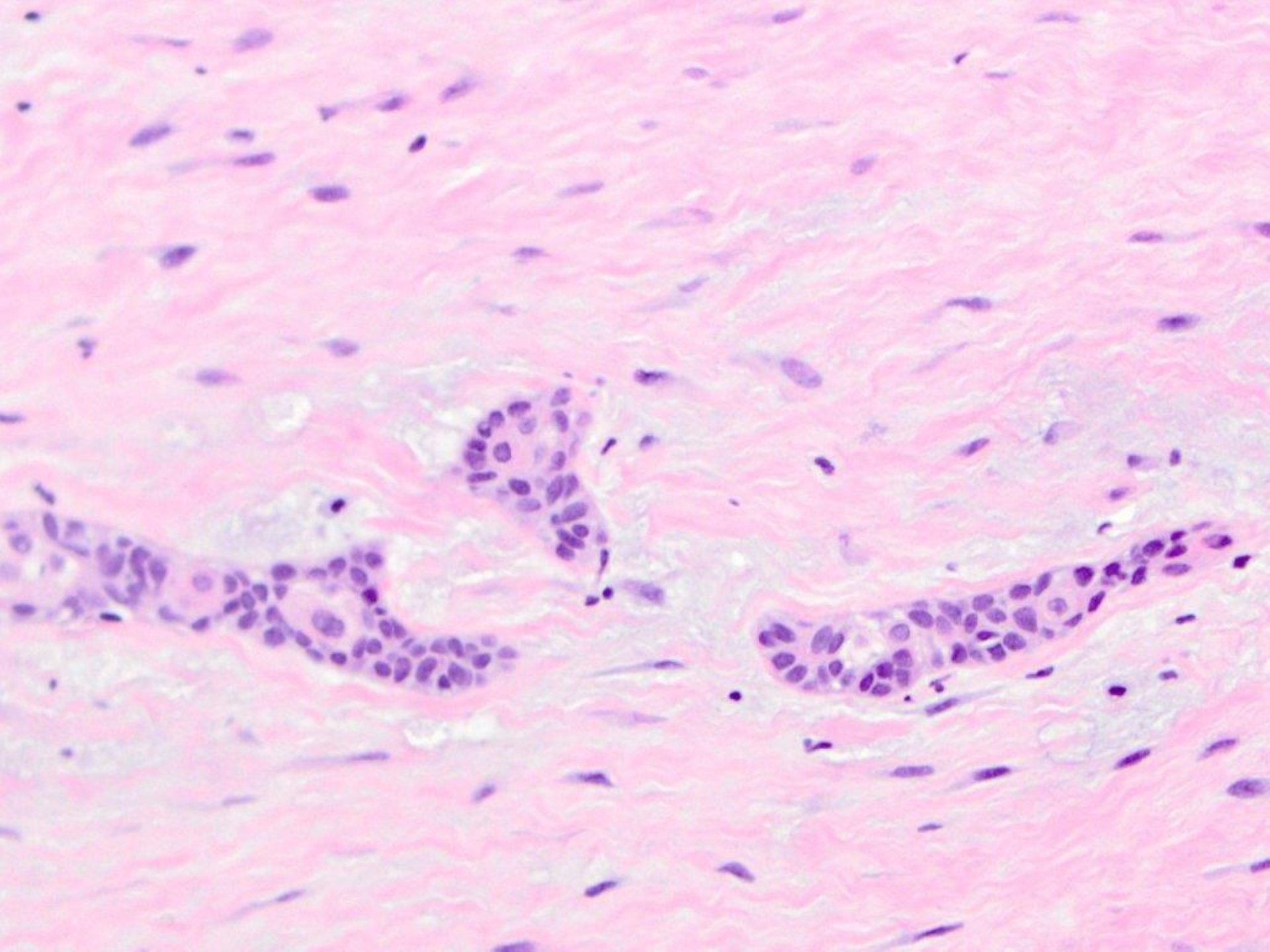
glandular odontogenic cyst [with Rushton bodies]

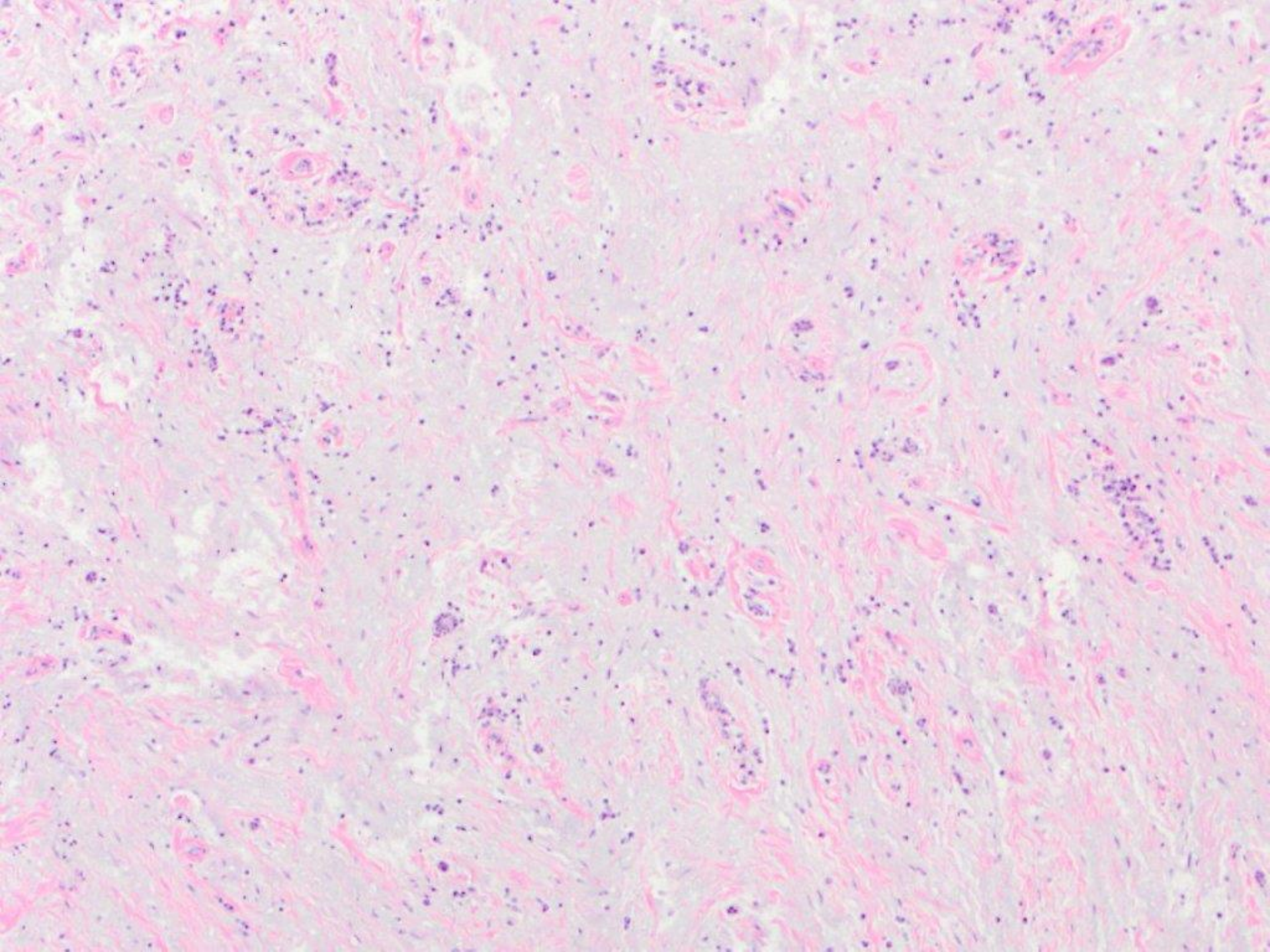


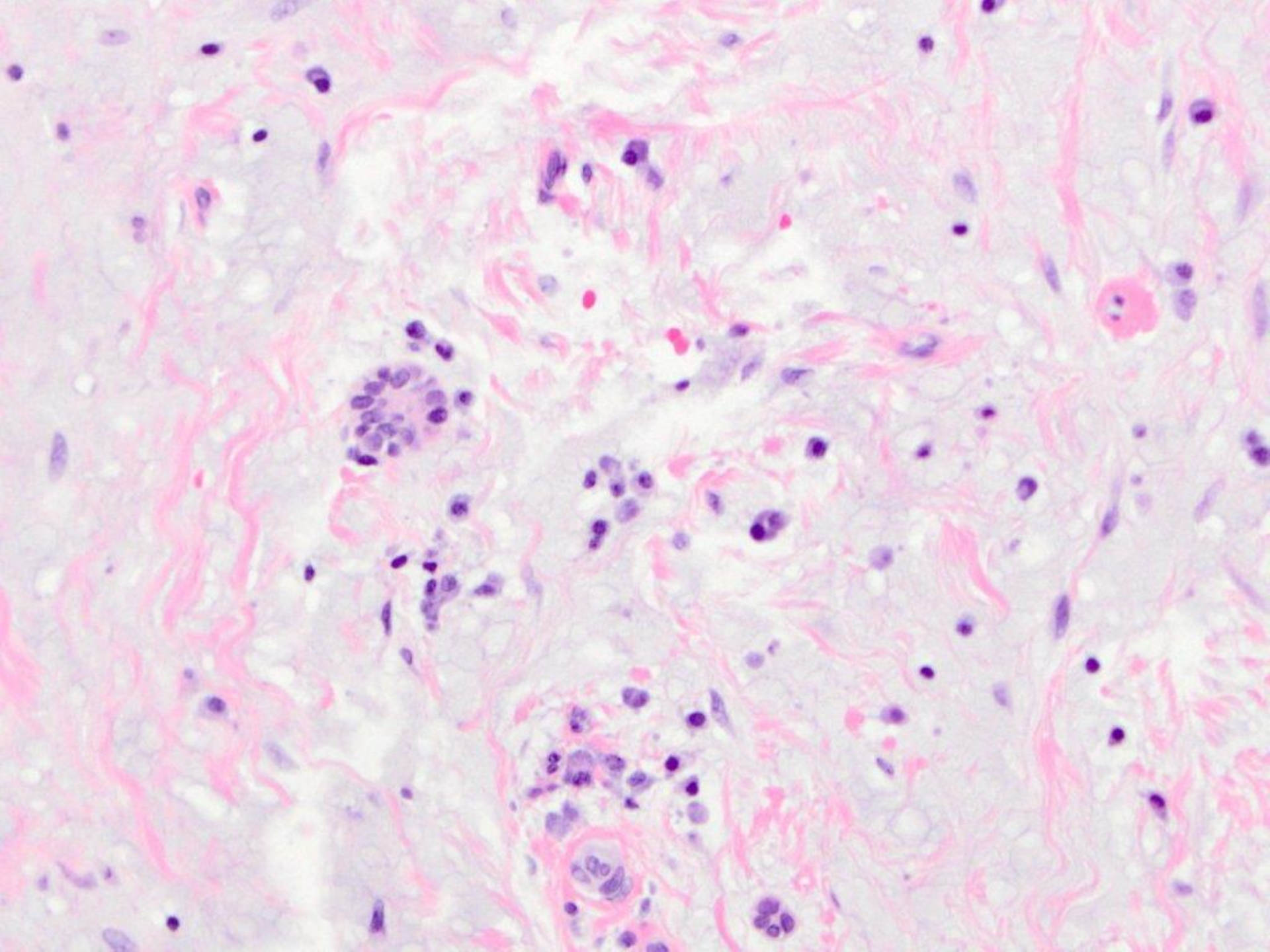


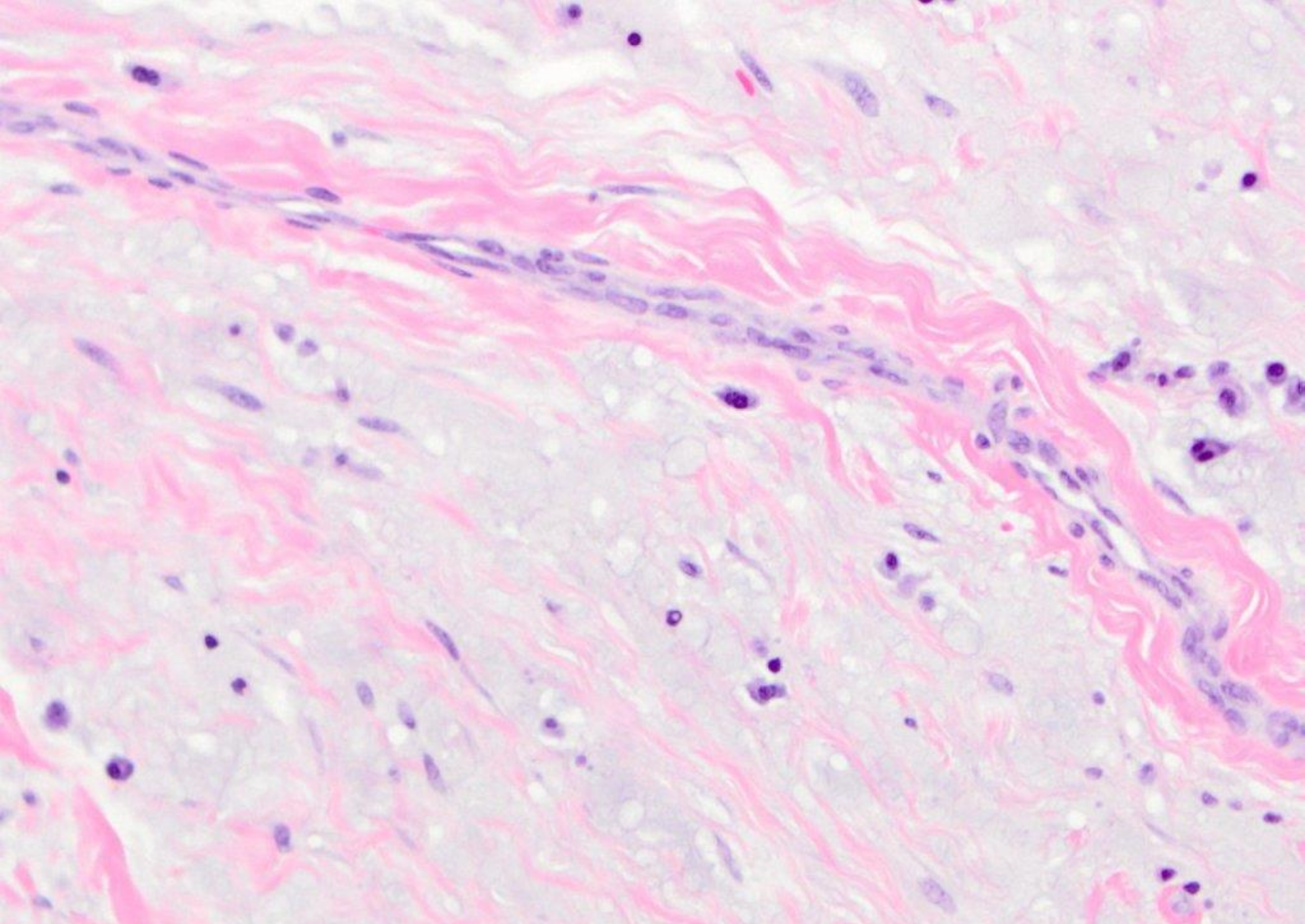






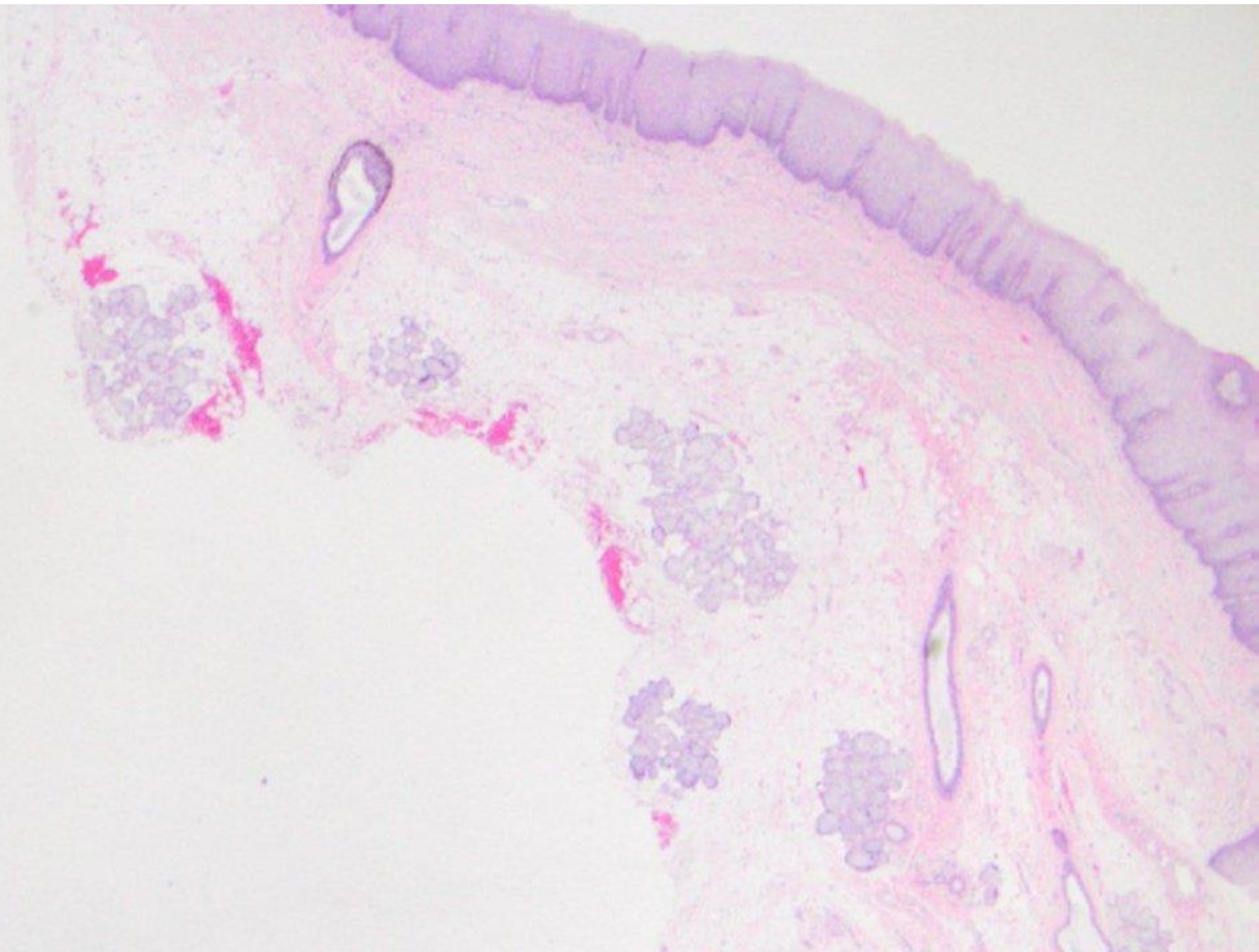


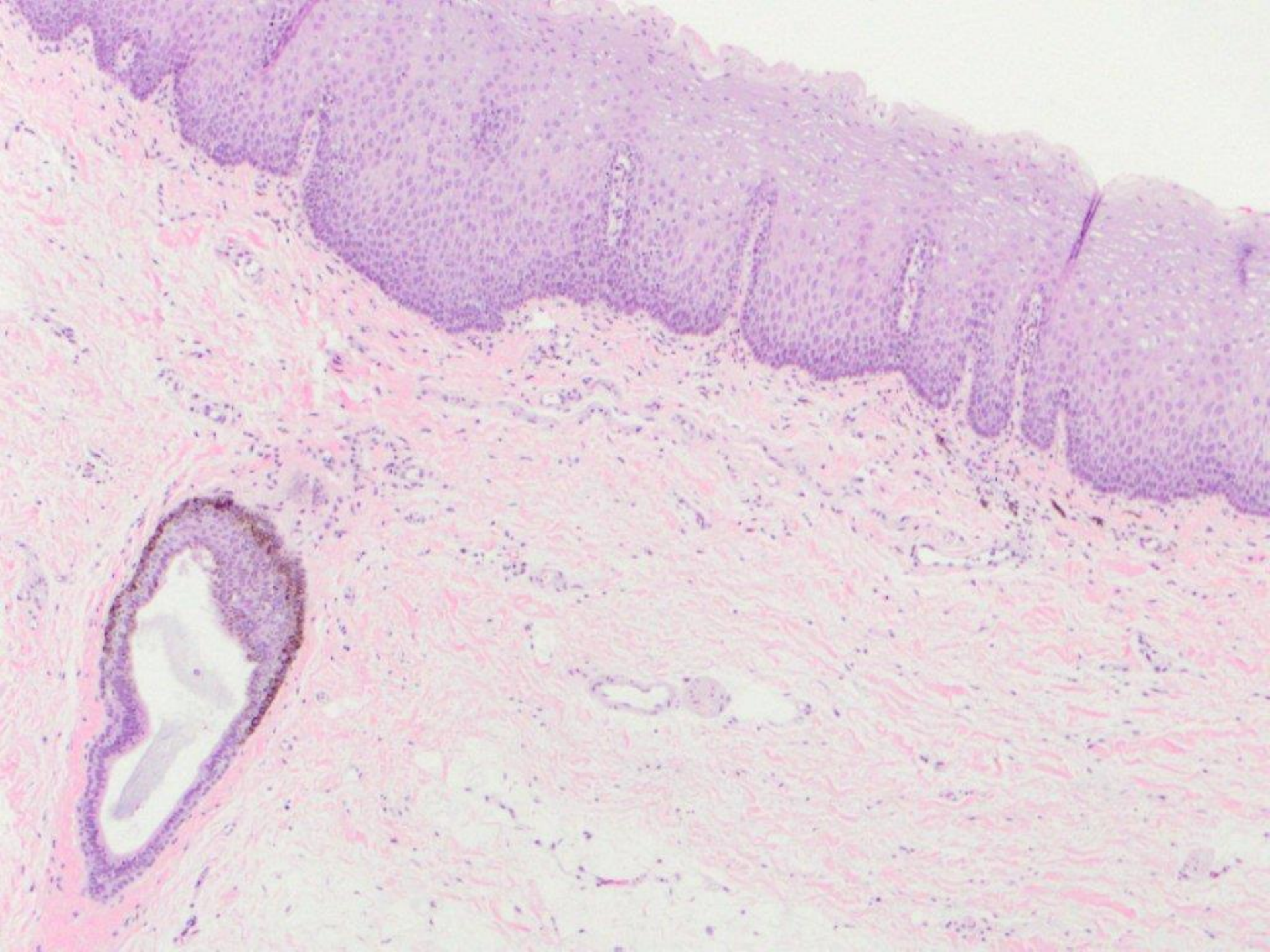


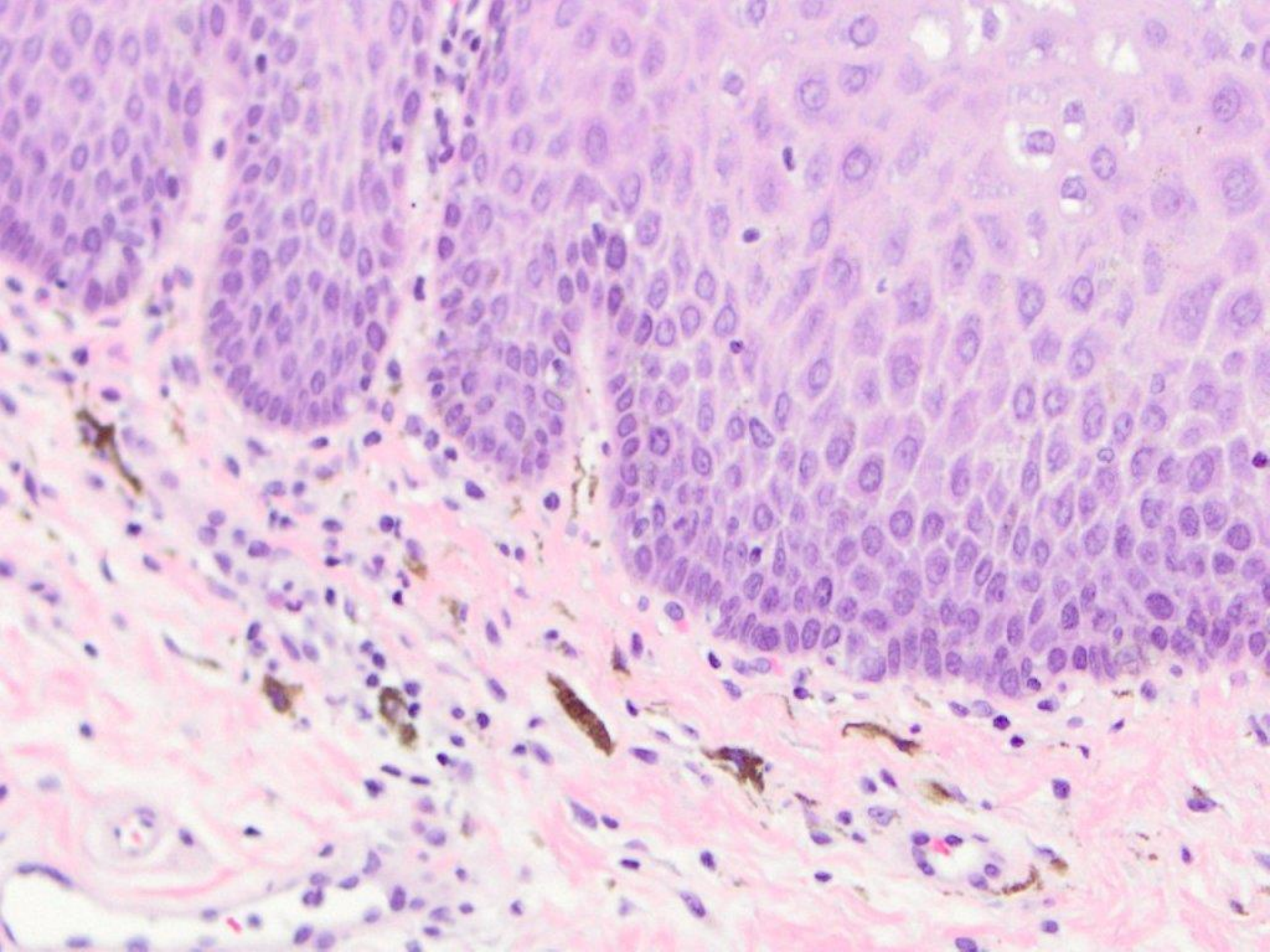


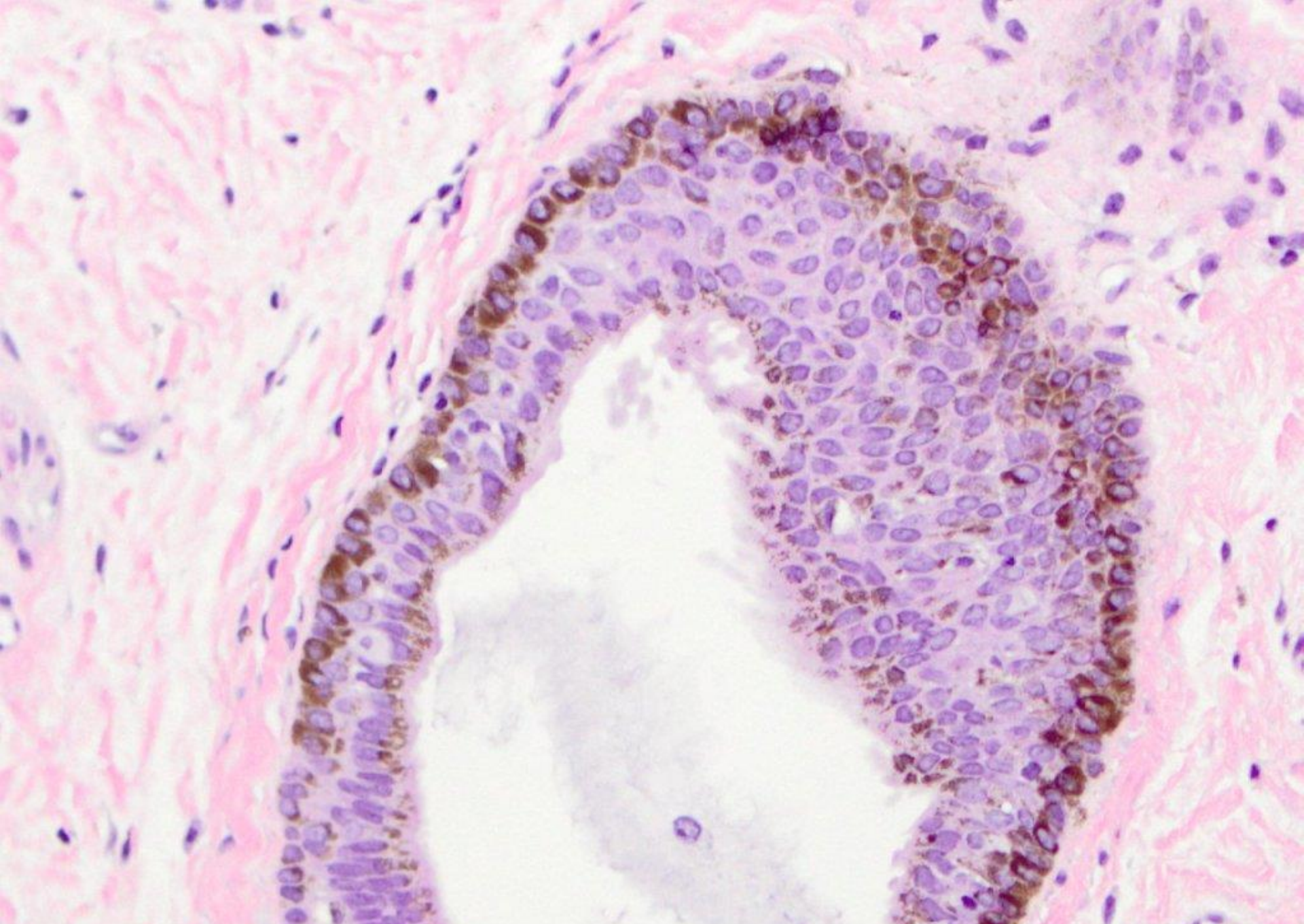
central odontogenic fibroma

described as a well-defined brown macule, soft/hard palate junction



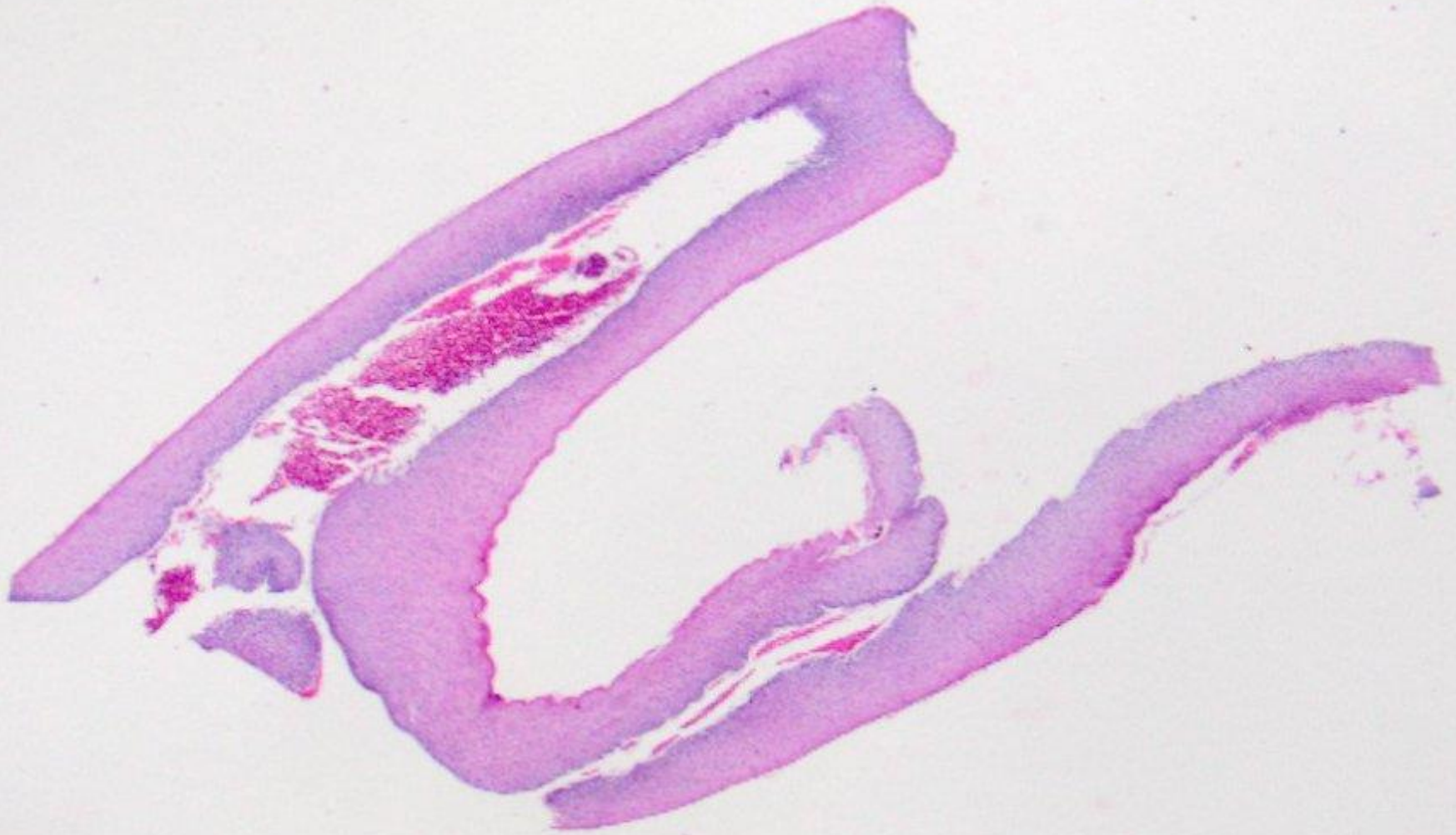


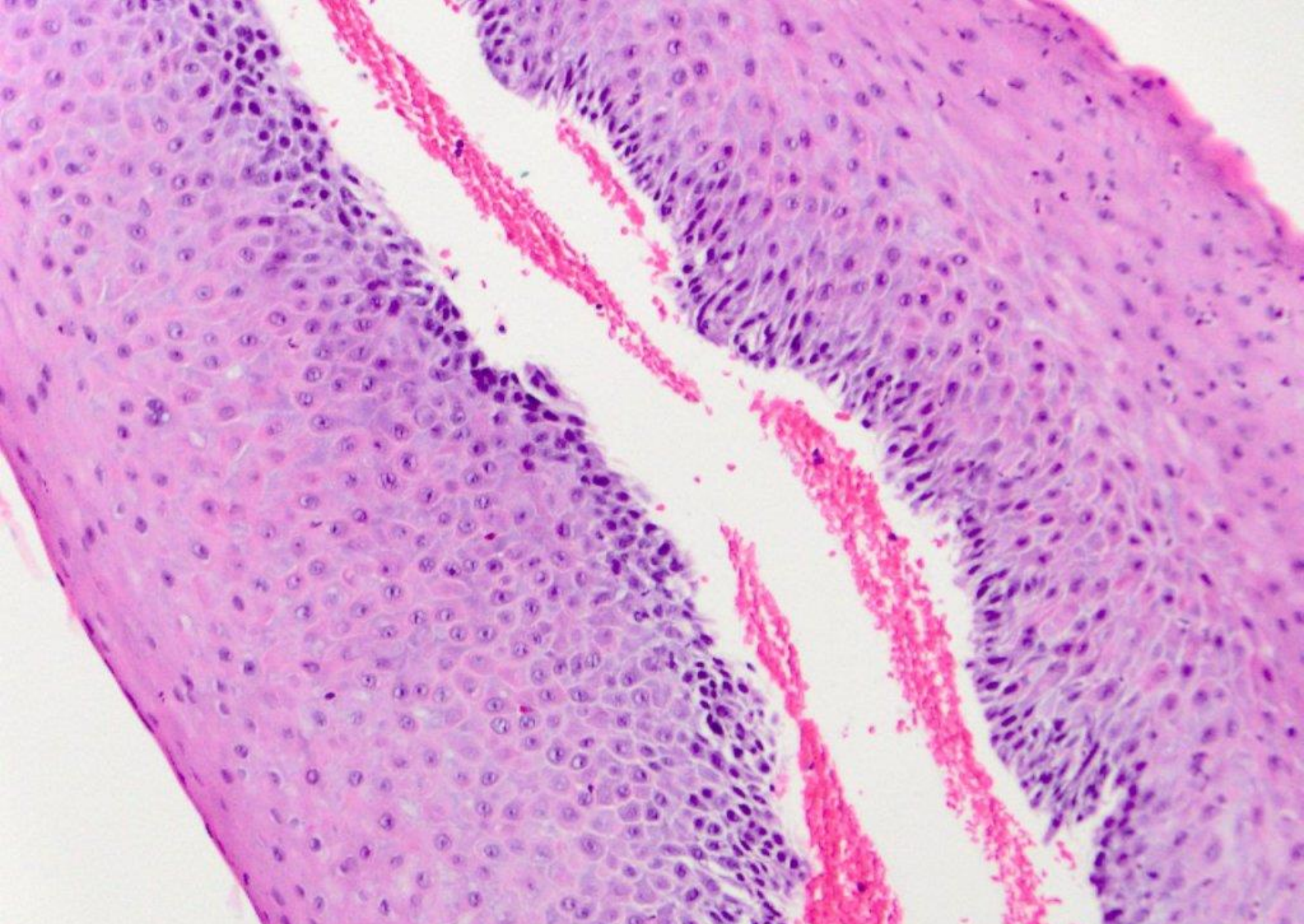




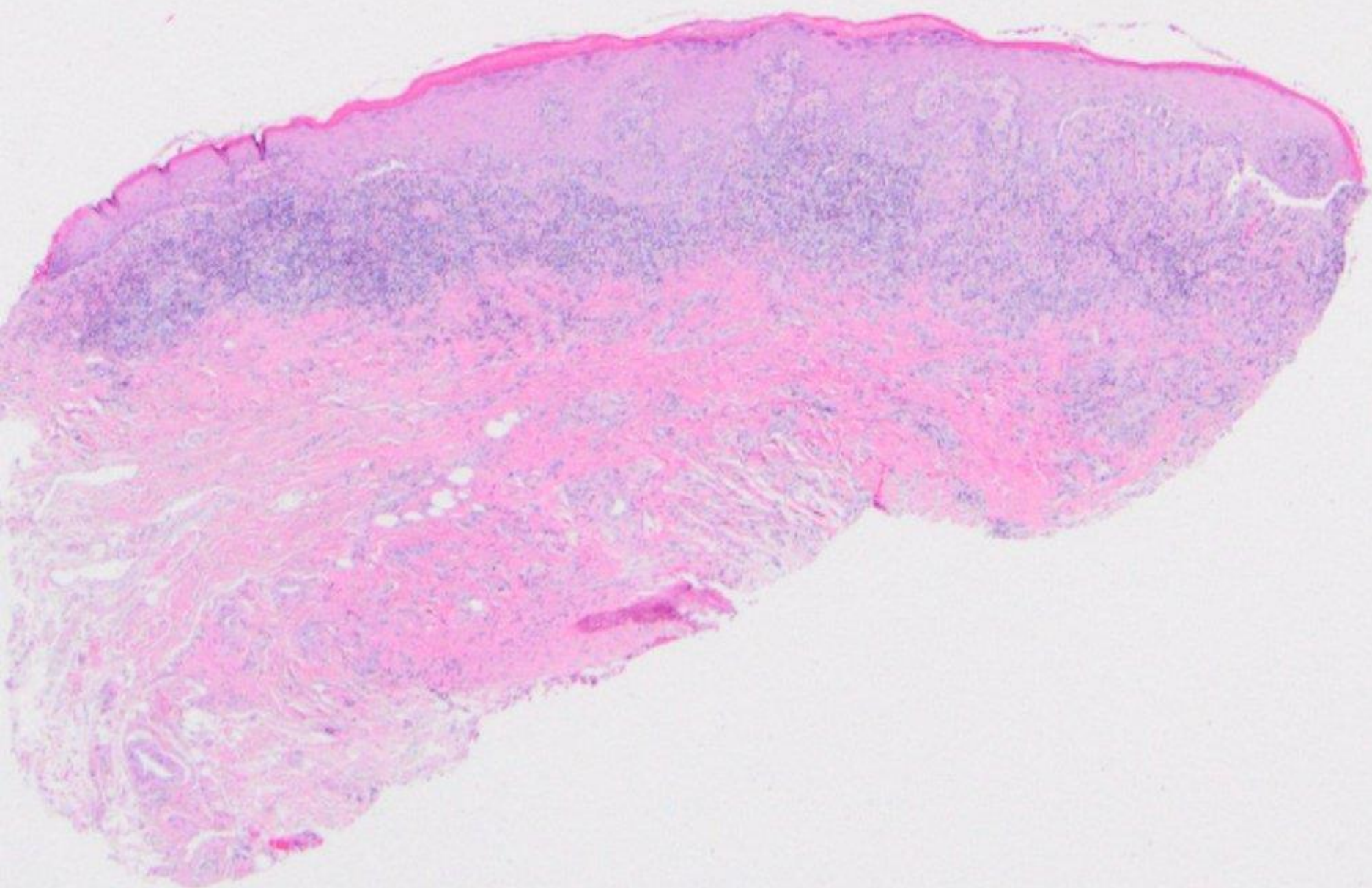
oral melanotic macule [with melanin pigment in the salivary excretory duct]

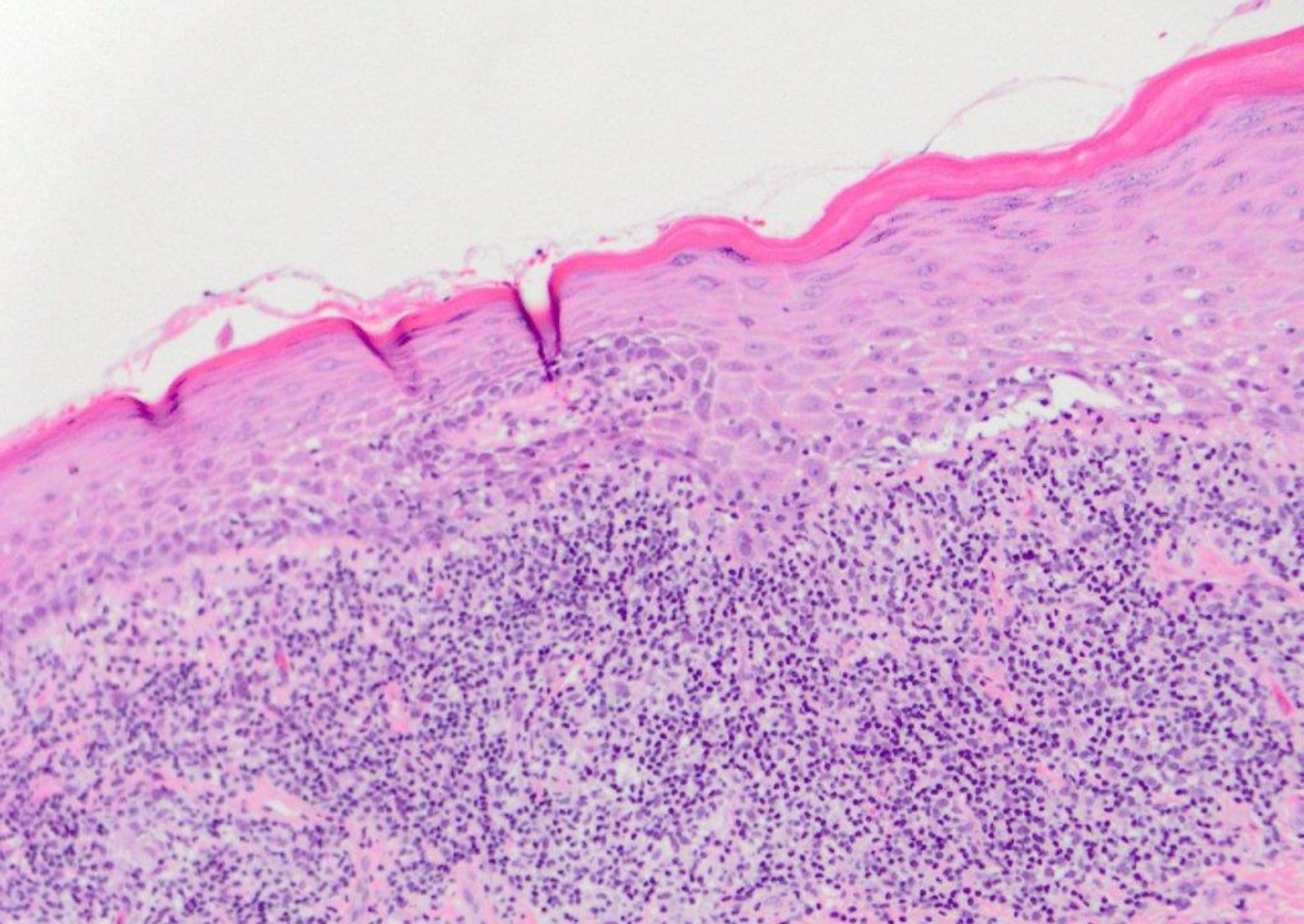
described as an erosive lesion of the buccal mucosa



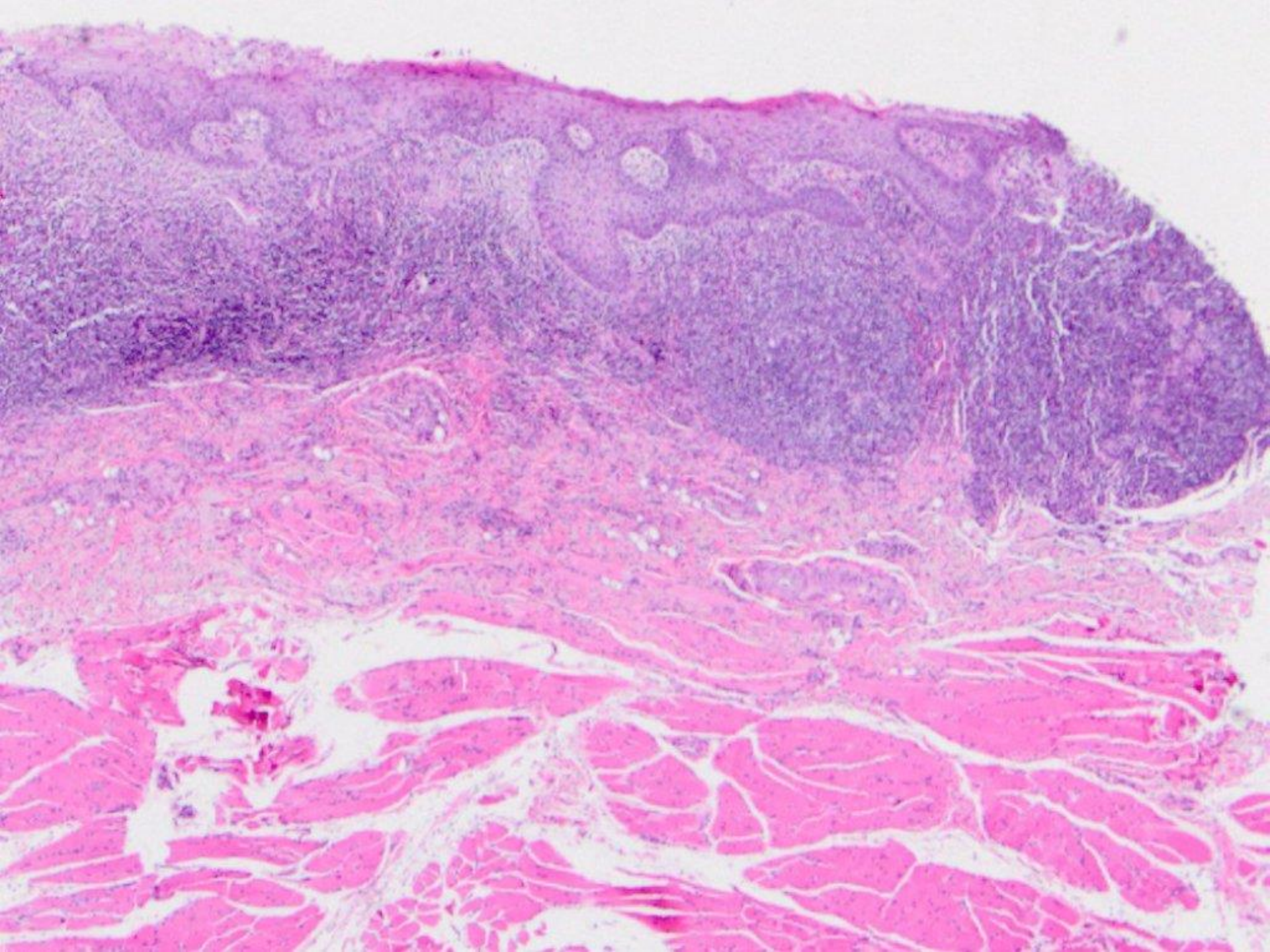


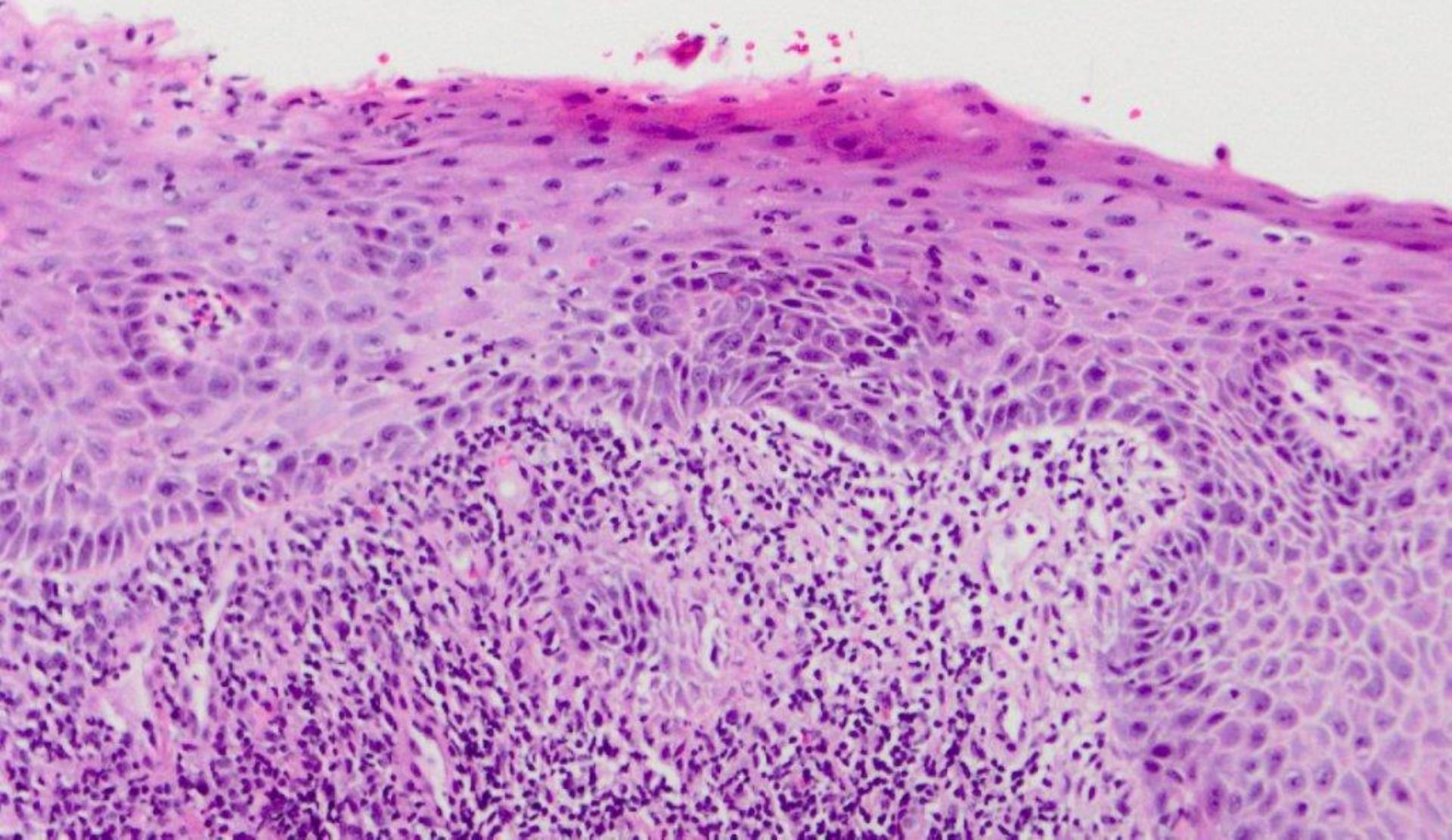
pemphigoid [subepithelial vesiculoerosive process; no connective tissue]

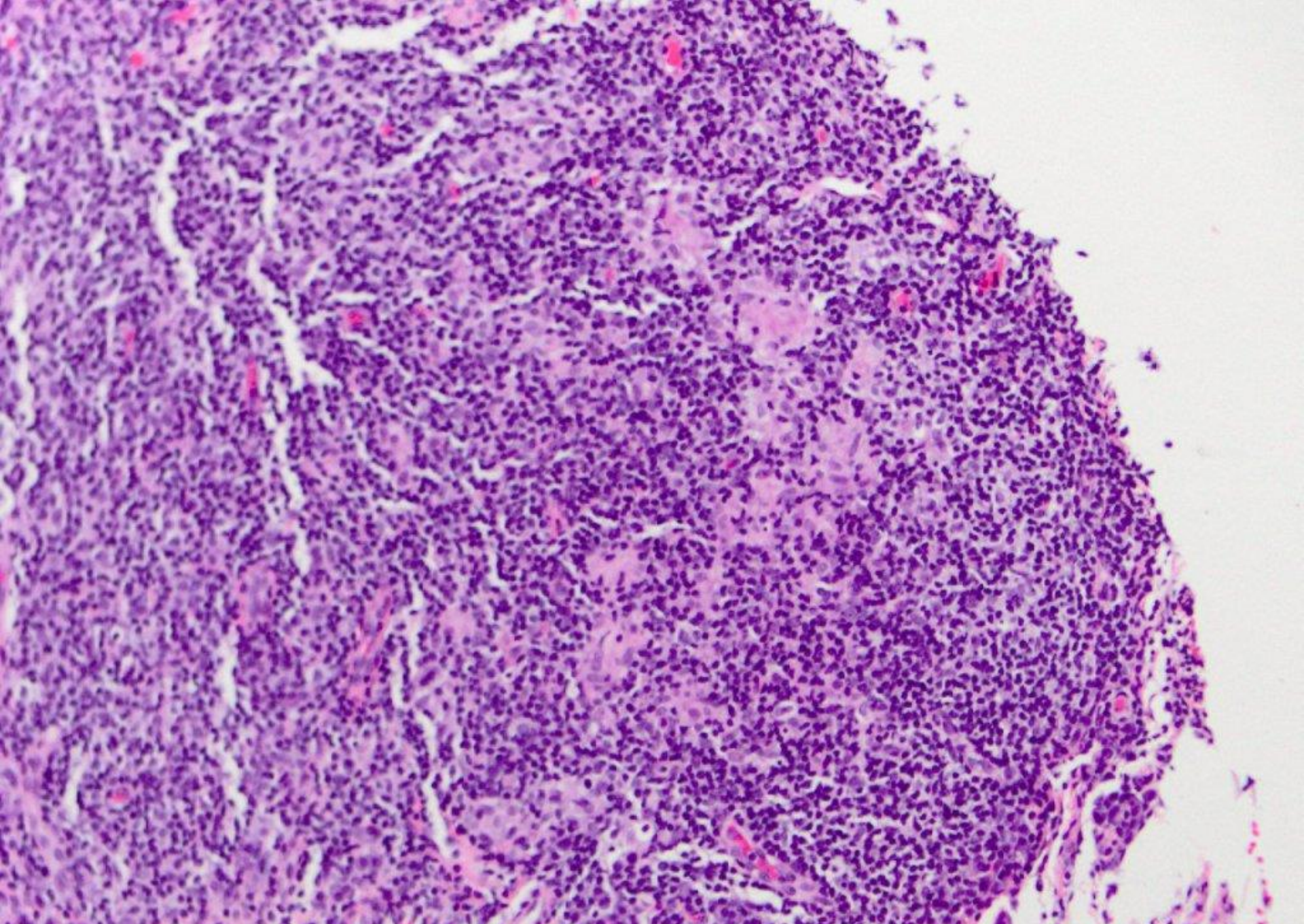




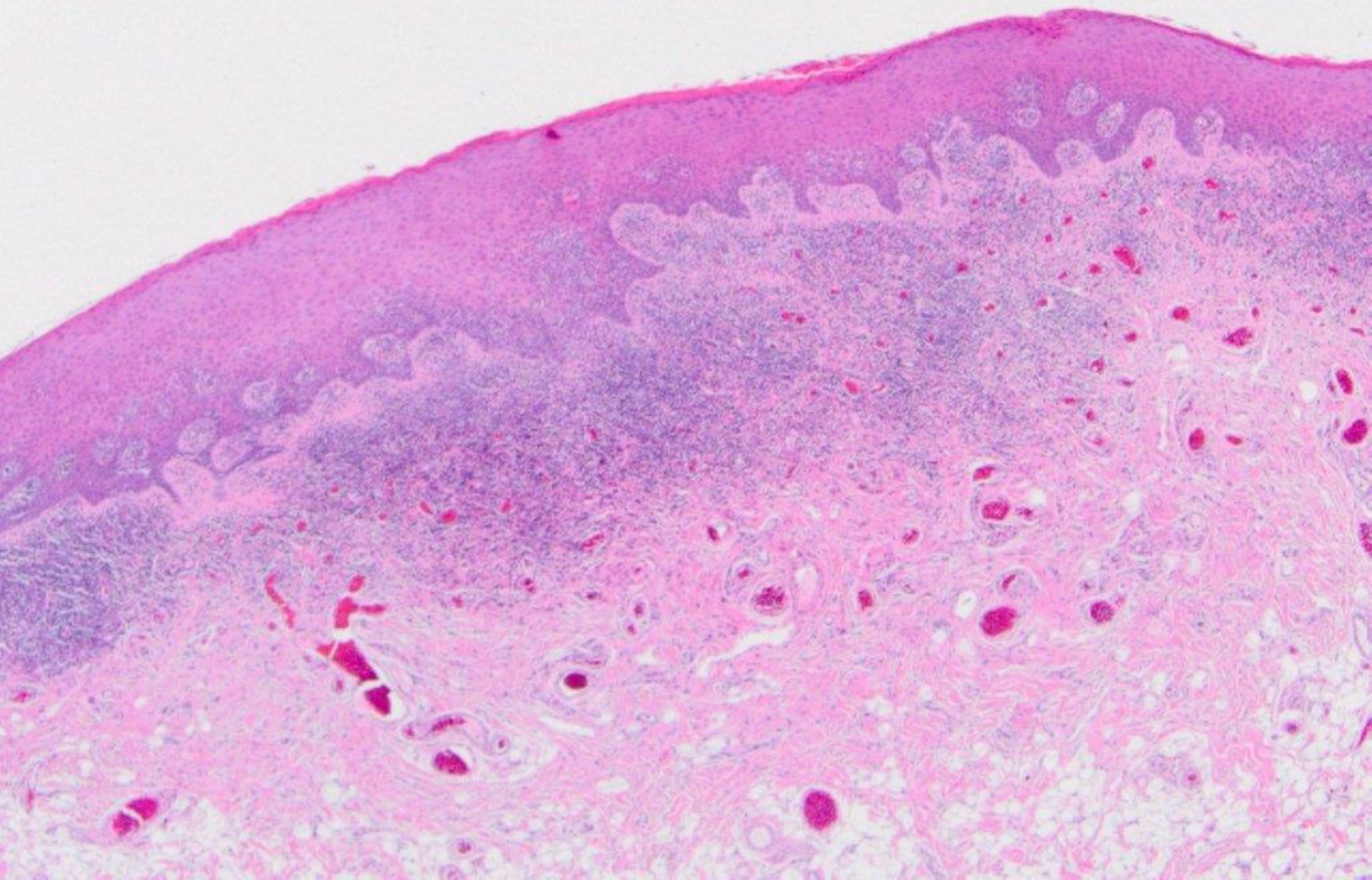
lichen planus

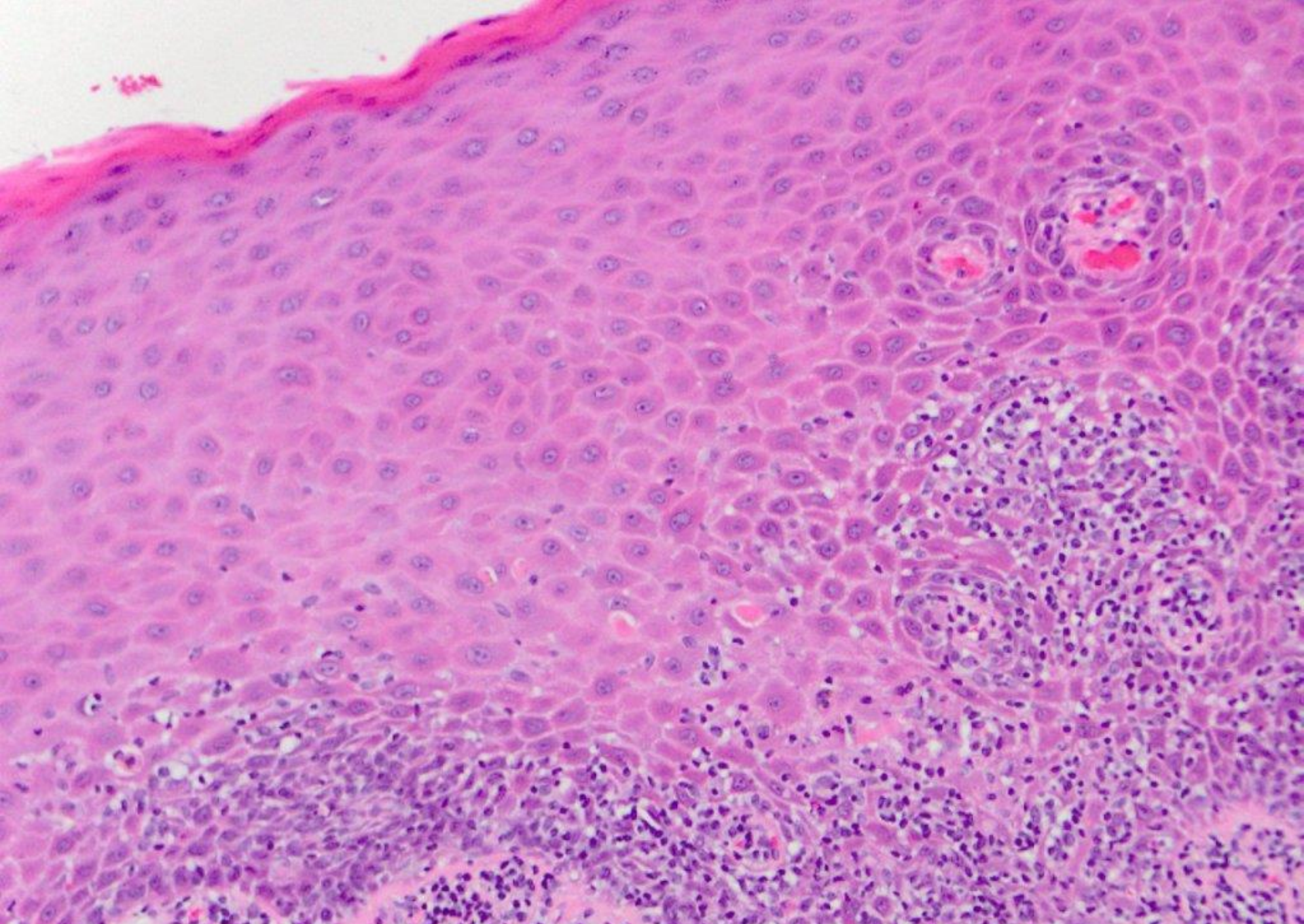




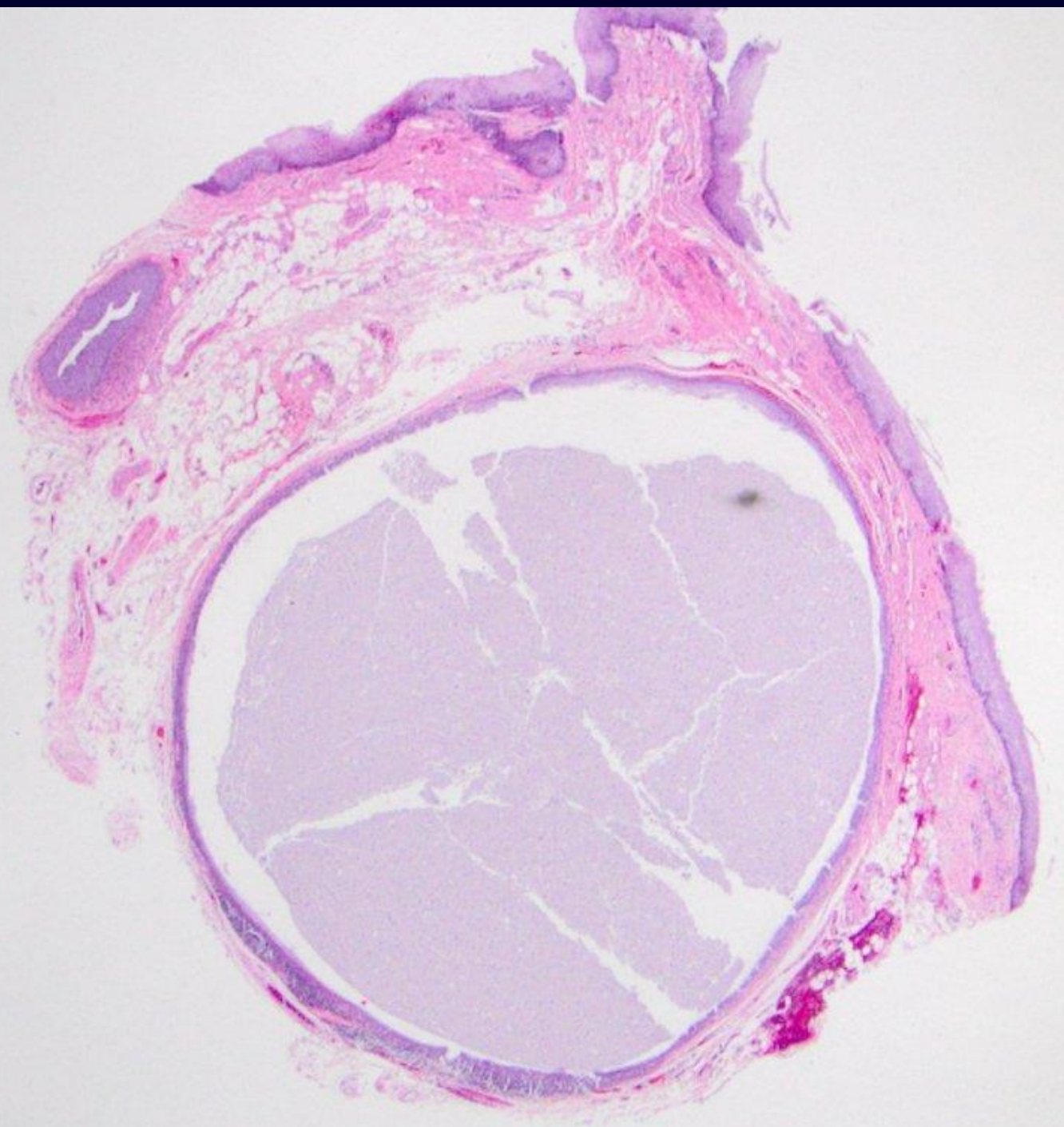


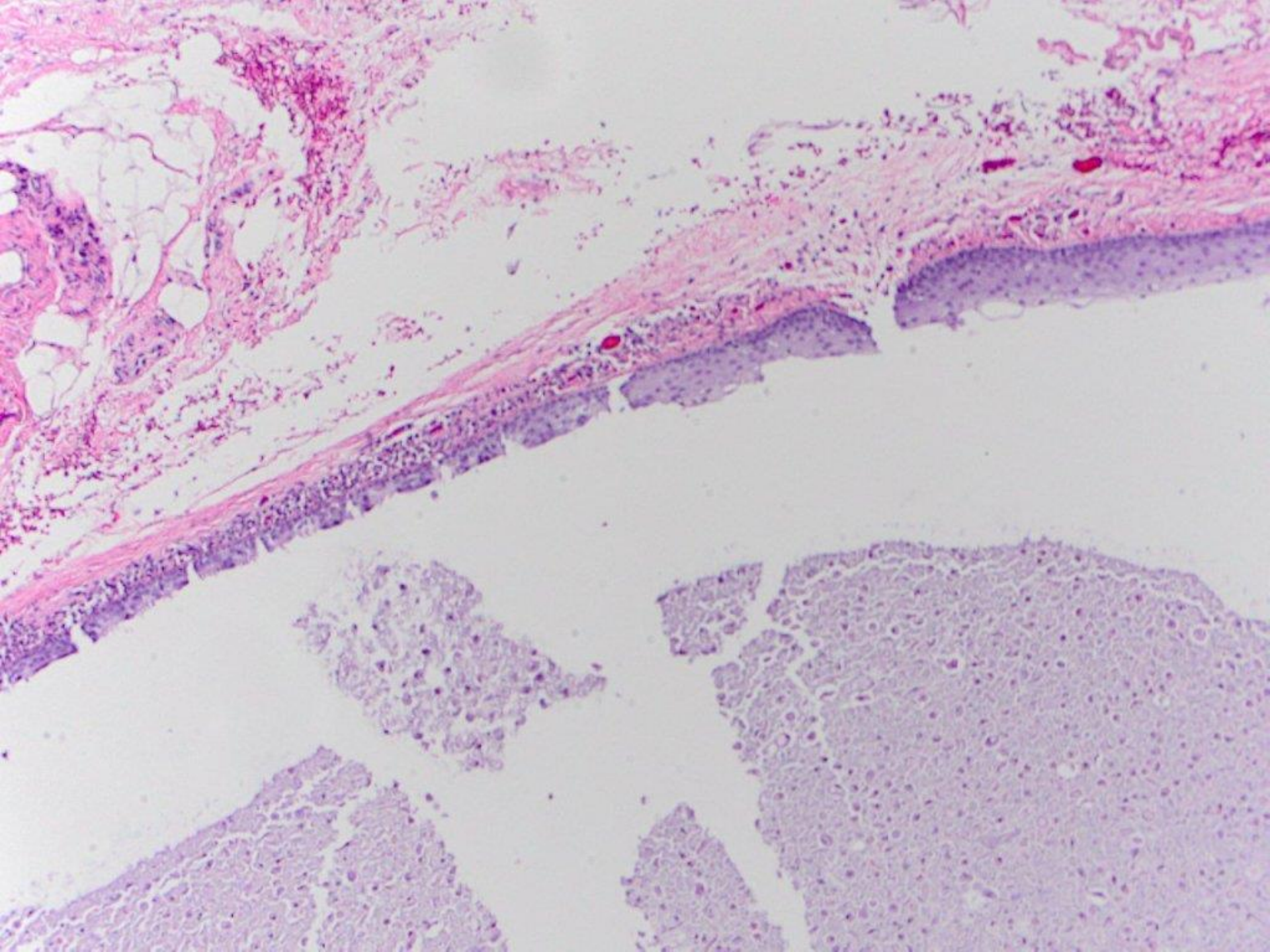
lichen planus, with microgranulomata

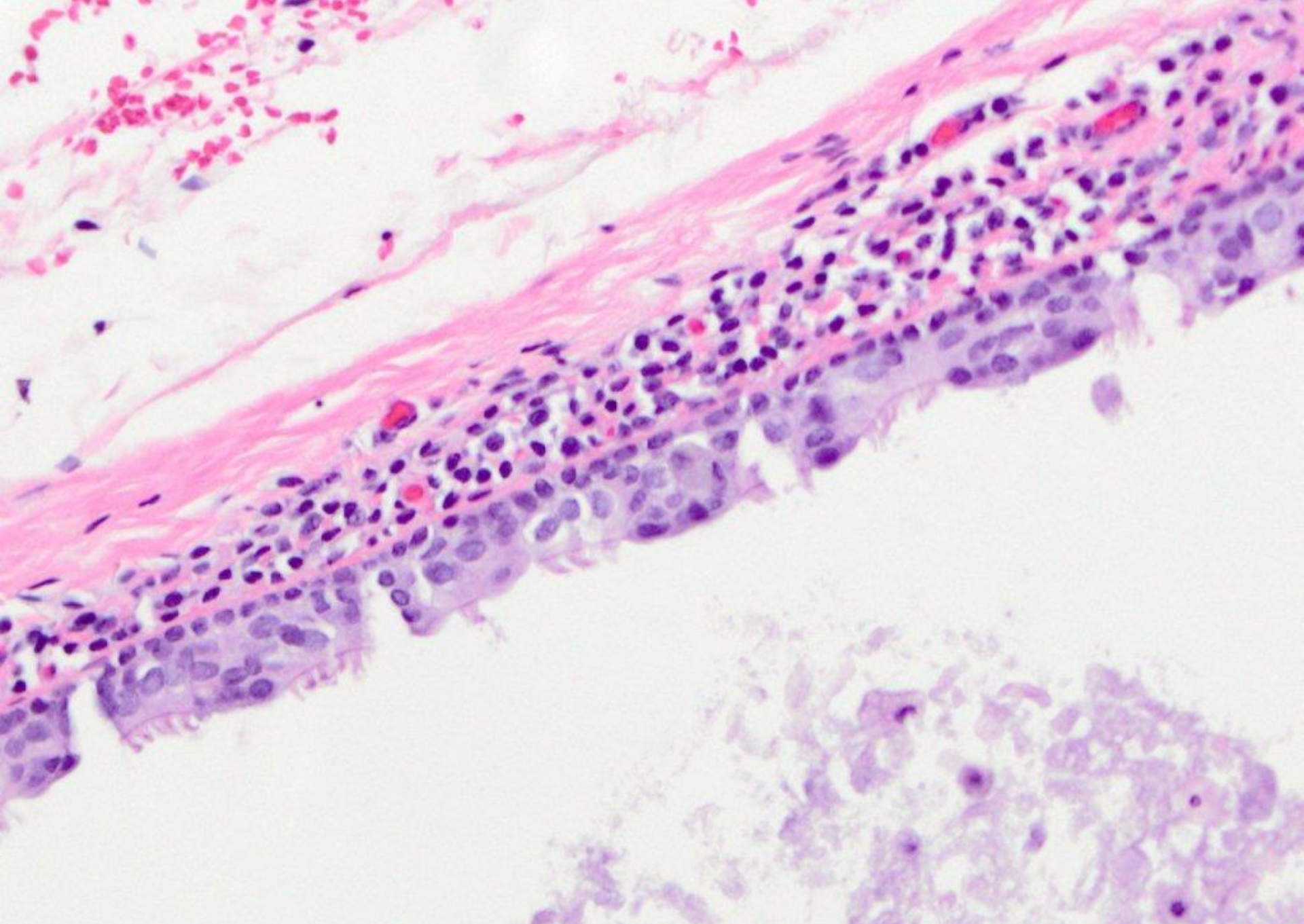




lichen planus, with Civatte (colloid/hyaline) bodies

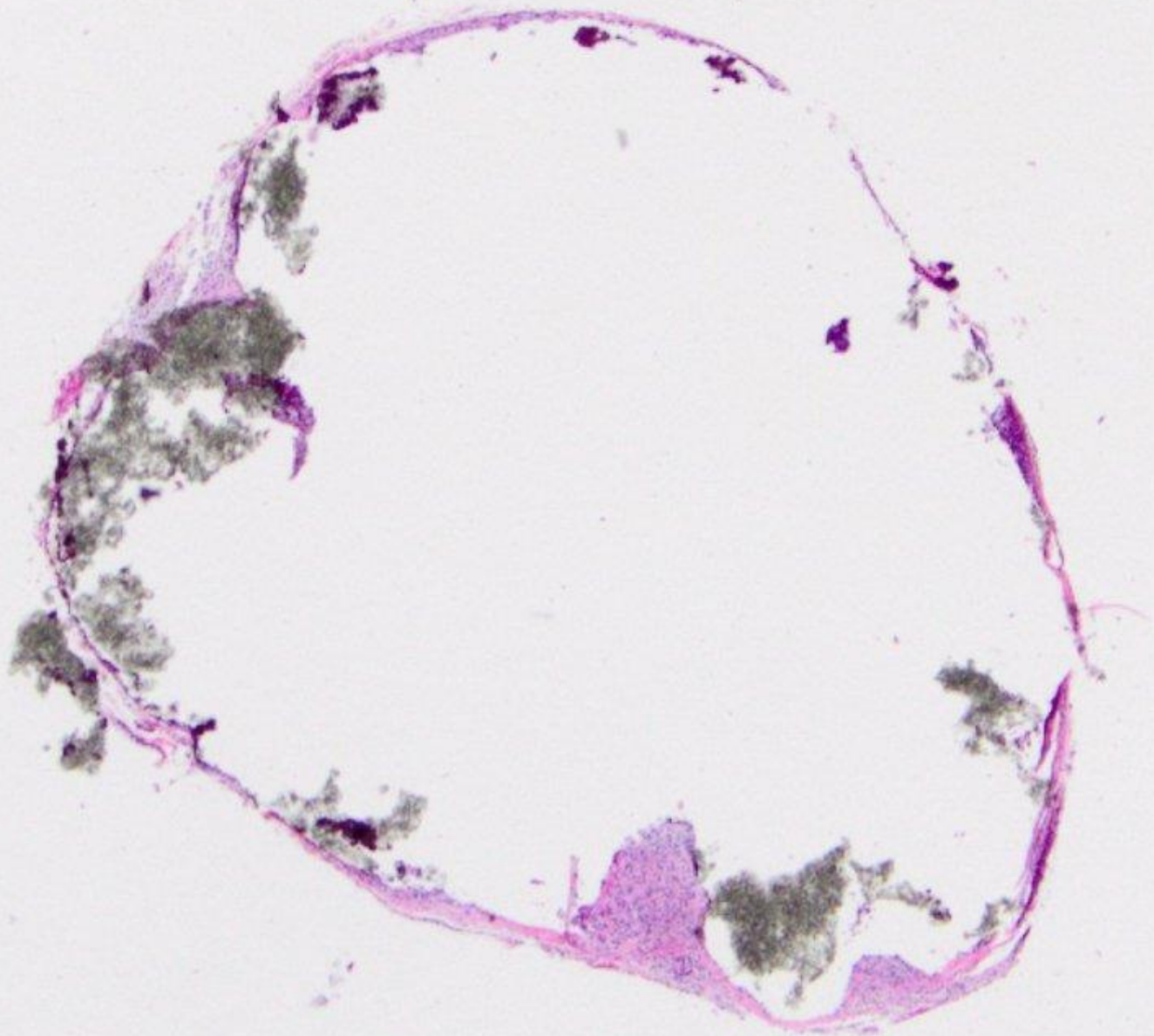


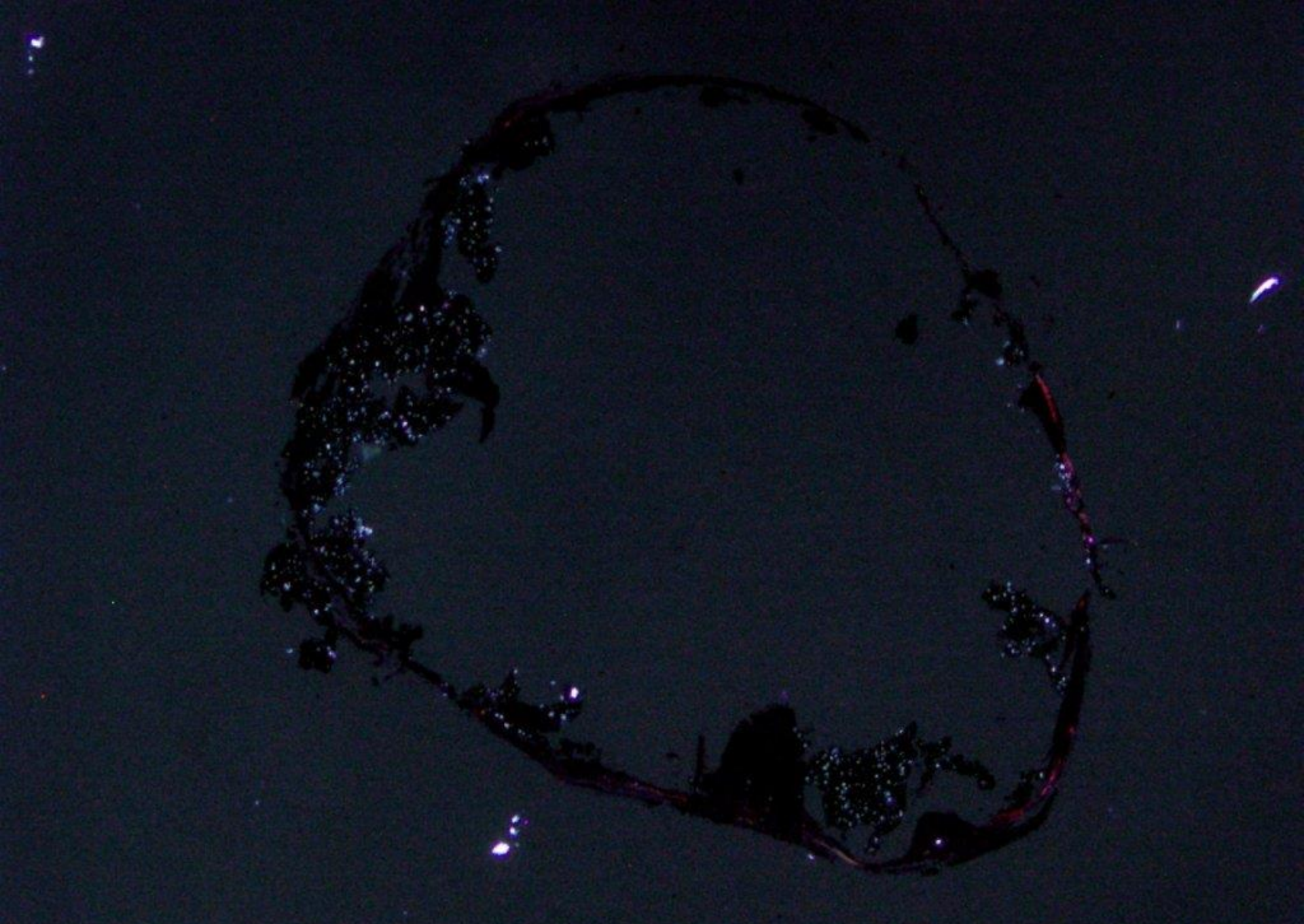



salivary duct cyst (mucocele, retention type)

described as a “foreign body” [gingiva, #27/28 area; #27 has PFM crown]





polarizable foreign body, suggestive of adhesive/cement